



## Hypophosphatasia

Mark E Nunes, MD<sup>1</sup>

Created: November 20, 2007; Revised: March 30, 2023.

### Summary

#### Clinical characteristics

Hypophosphatasia is characterized by defective mineralization of growing or remodeling bone, with or without root-intact tooth loss, in the presence of low activity of serum and bone alkaline phosphatase. Clinical features range from stillbirth without mineralized bone at the severe end to pathologic fractures of the lower extremities in later adulthood at the mild end. While the disease spectrum is a continuum, seven clinical forms of hypophosphatasia are usually recognized based on age at diagnosis and severity of features:

*Perinatal (severe):* Characterized by pulmonary insufficiency and hypercalcemia

*Perinatal (benign):* Prenatal skeletal manifestations that slowly resolve into one of the milder forms

*Infantile:* Onset between birth and age six months of clinical features of rickets without elevated serum alkaline phosphatase activity

*Severe childhood (juvenile):* Variable presenting features progressing to rickets

*Mild childhood:* Low bone mineral density for age, increased risk of fracture, and premature loss of primary teeth with intact roots

*Adult:* Characterized by stress fractures and pseudofractures of the lower extremities in middle age, sometimes associated with early loss of adult dentition

*Odontohypophosphatasia:* Characterized by premature exfoliation of primary teeth and/or severe dental caries without skeletal manifestations

#### Diagnosis/testing

The clinical diagnosis of hypophosphatasia can be established in a proband with suggestive clinical, laboratory, and radiographic features by identification of reduced serum unfractionated alkaline phosphatase activity

and/or identification on molecular genetic testing of biallelic loss-of-function *ALPL* variants or a heterozygous *ALPL* variant with dominant-negative effect.

## Management

*Targeted therapy:* Asfotase alfa (Strensiq®) enzyme replacement therapy (ERT) has been shown to improve pulmonary function, calcium homeostasis / bone health, and survival in individuals with the infantile and early childhood (juvenile) type of hypophosphatasia. There is growing experience with ERT in individuals with the perinatal (severe) type and emerging experience with ERT in treating osteomalacia in adults.

*Supportive care:* For the perinatal (severe) type: expectant management and family support; respiratory support; management of calcium homeostasis and bone health per endocrinologist and orthopedist; pain management; neurosurgical management of craniosynostosis; management of kidney disease per nephrologist; dental care. For the infantile and early childhood (juvenile) types: respiratory support; management of calcium homeostasis and bone health per endocrinologist and orthopedist; pain management; treatment of seizures with vitamin B<sub>6</sub>; neurosurgical management of craniosynostosis; management of kidney disease per nephrologist; dental care. For all other types: dental care starting at age one year; nonsteroidal anti-inflammatory drugs for osteoarthritis, bone pain, and osteomalacia; internal fixation for pseudofractures and stress fractures. In adult hypophosphatasia, there is limited experience in treating osteomalacia with teriparatide.

*Surveillance:* Monitor calcium homeostasis and bone health per endocrinologist, nephrologist, and orthopedist; physical medicine and rehabilitation, physical therapy, and occupational therapy evaluations as needed; monitor children with infantile type for increased intracranial pressure secondary to craniosynostosis; nephrology evaluations as needed for kidney disease; neurology evaluations as needed for seizures; dental visits twice yearly starting at age one year.

*Agents/circumstances to avoid:* Bisphosphonates and excess vitamin D; teriparatide is contraindicated in children.

*Pregnancy management:* The use of asfotase alfa (Strensiq®) ERT during human pregnancy has not been extensively studied; therefore, any potential risk to the fetus of a pregnant woman taking this therapy during pregnancy is unknown.

## Genetic counseling

Perinatal and infantile hypophosphatasia are typically inherited in an autosomal recessive manner. The milder forms, especially adult and odontohypophosphatasia, may be inherited in an autosomal recessive or autosomal dominant manner depending on the effect that the *ALPL* pathogenic variant has on TNSALP (alkaline phosphatase, tissue-nonspecific isozyme) activity.

*Autosomal recessive hypophosphatasia:* If both parents are known to be heterozygous for an *ALPL* pathogenic variant, each sib of an affected individual has at conception a 25% chance of inheriting biallelic pathogenic variants and being affected, a 50% chance of being heterozygous, and a 25% chance of inheriting neither of the familial pathogenic variants. Depending on the *ALPL* pathogenic variant, heterozygous sibs may be either clinically asymptomatic (manifesting only biochemical abnormality) or have milder clinical symptoms than the proband.

*Autosomal dominant hypophosphatasia:* All individuals reported to date with hypophosphatasia caused by a heterozygous *ALPL* variant with a dominant-negative effect inherited the *ALPL* pathogenic variant from a parent (who may or may not have clinical manifestations of hypophosphatasia). Unless an individual with autosomal dominant hypophosphatasia has children with an individual who has a heterozygous or biallelic *ALPL* pathogenic variant(s), offspring have a 50% chance of inheriting the *ALPL* pathogenic variant.

Once the *ALPL* pathogenic variant(s) have been identified in an affected family member, heterozygote testing for at-risk relatives, prenatal testing, and preimplantation genetic testing for hypophosphatasia are possible. Recurrence of perinatal and infantile hypophosphatasia may reliably be identified by prenatal ultrasound examination.

## Diagnosis

No consensus clinical diagnostic criteria for hypophosphatasia have been published.

## Suggestive Findings

Hypophosphatasia **should be suspected** in probands with the following clinical, laboratory, and radiographic features.

### Clinical features

- Clinical features of infantile rickets: growth failure, craniotabes, craniosynostosis, blue sclerae, flail chest, costochondral enlargement ("rachitic rosary"), scoliosis, thickening of wrists, knees, and ankles, bowing of legs, lax ligaments, and hypotonia
- Premature loss of deciduous teeth beginning with the incisors. Unusually and characteristically, the dental root remains attached to the lost tooth. Dental caries and early loss or extraction of adult teeth is also seen (see Figure 1).
- Vitamin B<sub>6</sub> (pyridoxine)-responsive seizures
- Bone pain

### Laboratory features

- **Hypercalciuria** particularly during the first year of life with or without hypercalcemia
- Typically normal serum calcium and ionized calcium. Note: May be elevated, particularly in the first year of life.
- Typically normal serum and urine inorganic phosphate. Note: May be elevated.
- Normal serum vitamin D (25-hydroxy and 1,25-dihydroxy) and parathyroid hormone
- **Elevated plasma vitamin B<sub>6</sub>** without oral supplementation
- **Elevated serum pyridoxal 5'-phosphate (PLP)**, a biologically active metabolite of vitamin B<sub>6</sub>. Note: (1) Reference laboratories may measure PLP and report as "vitamin B<sub>6</sub>." (2) Use of multivitamin or calcium supplements containing vitamin B<sub>6</sub> within a week of assaying serum PLP may lead to false positive results.
- **Elevated urine phosphoethanolamine (PEA) and proline** on urine amino acid chromatogram. Note: (1) Urine PEA may be elevated with other metabolic bone diseases. (2) Urine PEA may be normal in affected individuals and can be elevated in asymptomatic heterozygotes.
- **Elevated urine inorganic pyrophosphate (PPi)**. Note: (1) Assay is not available in North American clinical laboratories. (2) Asymptomatic heterozygotes can have elevated urine PPi.
- **Reduced serum unfractionated alkaline phosphatase (ALP) activity**. Note: (1) Transient increases in serum ALP activity can occur during pregnancy, with liver disease, and after acute fracture or surgery. Thus, serial measurements may be necessary in toddlers with unexplained fractures. Quantitation of the activity of the bone isoform of ALP in serum may be necessary in the setting of liver disease. The bone isoform is heat labile; the liver isoform is heat stable. (2) Asymptomatic heterozygotes can have reduced serum ALP activity.

### Radiographic features

- Prenatal long bone bowing with osteochondral spurs

- Infantile rickets: undermineralized bones, widened-appearing sutures, brachycephaly, rachitic costochondral rib changes (see Figure 2A), flared metaphyses, poorly ossified epiphyses, and bowed long bones
- Focal bony defects of the metaphyses resembling radiolucent "tongues" (see Figure 2C) are fairly specific for childhood hypophosphatasia.
- Defective mineralization of growing/remodeling bone and/or teeth. Bone mineral content increases with age, and there may be improved mineralization during adolescence with decreased mineralization in middle age.
- Alveolar bone loss resulting in premature loss of deciduous teeth typically involving the anterior mandible, with the central incisors lost first. However, any tooth may be affected (see Figure 2B).
- Pathologic fractures. Growing children may have a predilection to metaphyseal fractures; however, epiphyseal and diaphyseal fractures are also seen. In adults, metatarsal stress fractures and femoral pseudofractures prevail.
- Osteomalacia with lateral pseudofractures ("Looser zones") in adult hypophosphatasia (see Figure 2D)

## Establishing the Diagnosis

The **clinical diagnosis** of hypophosphatasia **can be established** in a proband with suggestive clinical, radiographic, and laboratory features by identification of reduced serum unfractionated ALP activity.

The **molecular diagnosis can be established** in a proband with suggestive findings by identification of ONE of the following on molecular genetic testing (see Table 1):

- Biallelic loss-of-function *ALPL* variants
- A heterozygous *ALPL* variant with dominant-negative effect

Note: (1) Individuals with a heterozygous loss-of-function *ALPL* variant can have mild features of adult hypophosphatasia [Mornet et al 2021] (see Clinical Description, **heterozygous loss-of-function variants**). (2) Identification of a biallelic or heterozygous *ALPL* variant(s) of uncertain significance does not establish or rule out the diagnosis.

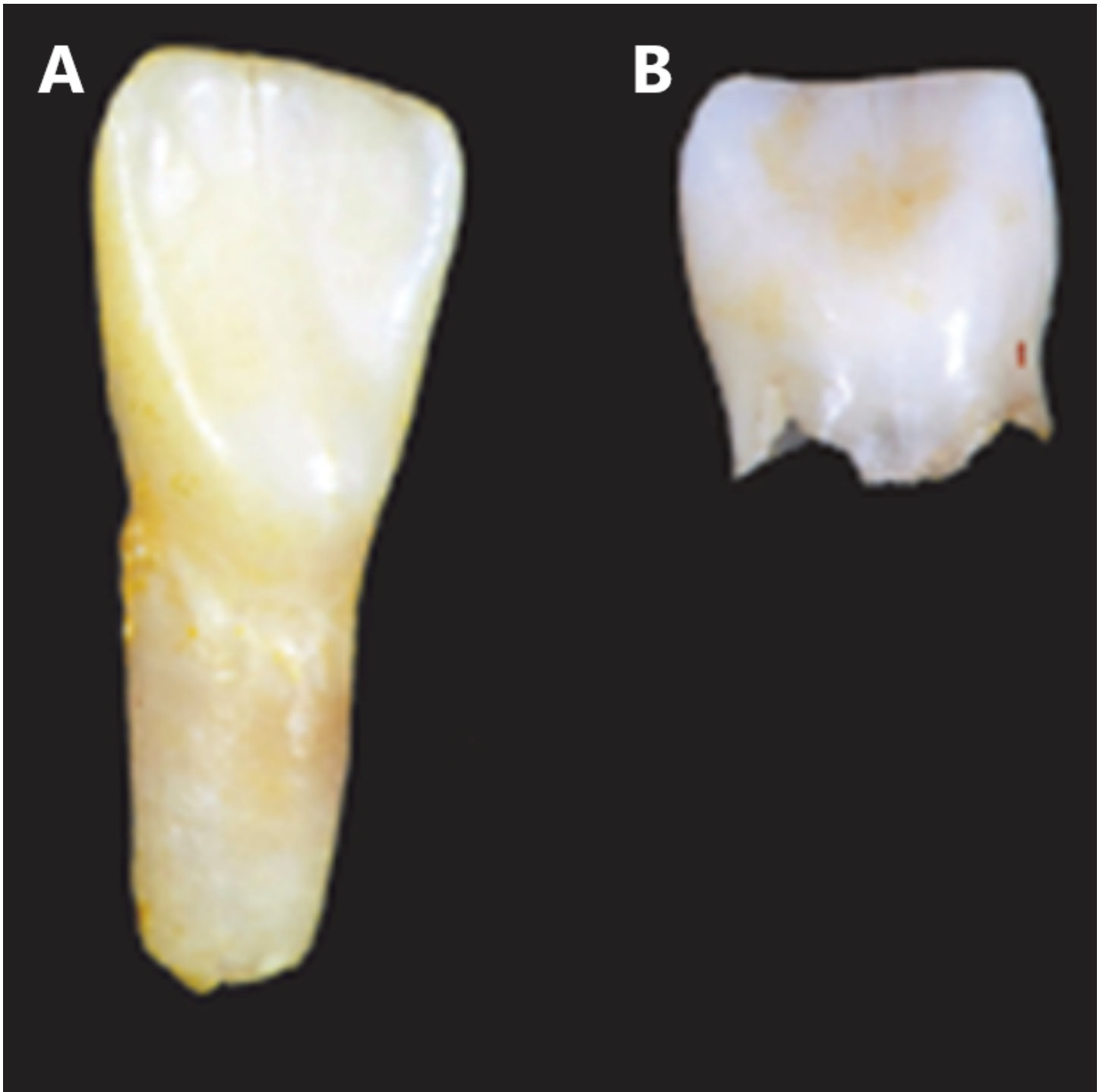
Molecular genetic testing approaches can include a combination of **gene-targeted testing** (single-gene testing, multigene panel) and **comprehensive genomic testing** (exome sequencing, genome sequencing) depending on the phenotype.

Gene-targeted testing requires that the clinician determine which gene(s) are likely involved, whereas genomic testing does not. Individuals with the distinctive findings described in Suggestive Findings are likely to be diagnosed using gene-targeted testing (see Option 1), whereas those with a phenotype indistinguishable from many other skeletal dysplasias are more likely to be diagnosed using genomic testing (see Option 2).

### Option 1

**Single-gene testing.** Sequence analysis of *ALPL* is performed first to detect missense, nonsense, and splice site variants and small intragenic deletions/insertions. Note: Depending on the sequencing method used, single-exon, multiexon, or whole-gene deletions/duplications may not be detected. If only one or no variant is detected by the sequencing method used, the next step is to perform gene-targeted deletion/duplication analysis to detect exon and whole-gene deletions or duplications.

**A multigene panel** that includes *ALPL* and other genes of interest (see Differential Diagnosis) may be considered to identify the genetic cause of the condition while limiting identification of variants of uncertain significance and pathogenic variants in genes that do not explain the underlying phenotype. Note: (1) The genes included in the panel and the diagnostic sensitivity of the testing used for each gene vary by laboratory and are likely to change over time. (2) Some multigene panels may include genes not associated with the condition



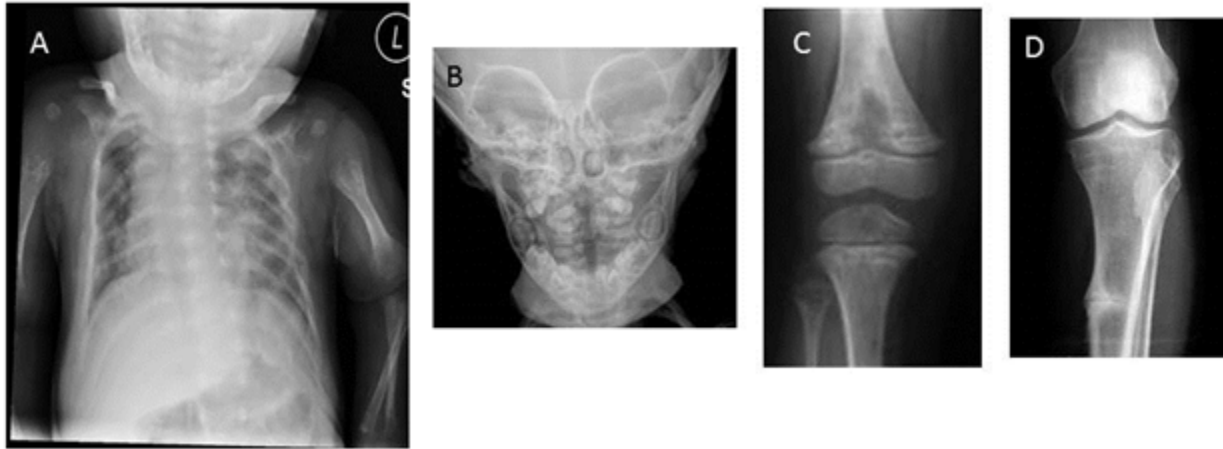
**Figure 1.** Lost incisors with and without hypophosphatasia

A. Hypophosphatasia: root intact

B. Normal: root absorbed

Reproduced with permission from Michael Whyte, MD

discussed in this *GeneReview*. (3) In some laboratories, panel options may include a custom laboratory-designed panel and/or custom phenotype-focused exome analysis that includes genes specified by the clinician. (4) Methods used in a panel may include sequence analysis, deletion/duplication analysis, and/or other non-sequencing-based tests.



**Figure 2.** Radiographic signs of hypophosphatasia

- A. Rachitic rib changes, flail chest, and metaphyseal dysplasia (proximal humerus) in infantile hypophosphatasia
- B. Alveolar bone loss surrounding molars in childhood (juvenile) hypophosphatasia
- C. Hypolucent "tongue" mid-metaphysis in childhood (juvenile) hypophosphatasia
- D. "Looser zone" (pseudofracture) in adult hypophosphatasia

For an introduction to multigene panels click [here](#). More detailed information for clinicians ordering genetic tests can be found [here](#).

## Option 2

When the phenotype is indistinguishable from many other skeletal dysplasias, **comprehensive genomic testing** (which does not require the clinician to determine which gene is likely involved) is likely the best option. **Exome sequencing** is most commonly used; **genome sequencing** is also possible.

For an introduction to comprehensive genomic testing click [here](#). More detailed information for clinicians ordering genomic testing can be found [here](#).

**Table 1.** Molecular Genetic Testing Used in Hypophosphatasia

Gene <sup>1</sup>	Method	Proportion of Pathogenic Variants <sup>2</sup> Detectable by Method
<i>ALPL</i>	Sequence analysis <sup>3</sup>	~95% <sup>4</sup>
	Gene-targeted deletion/duplication analysis <sup>5</sup>	<5% <sup>6</sup>



Table 1. continued from previous page.

Gene <sup>1</sup>	Method	Proportion of Pathogenic Variants <sup>2</sup> Detectable by Method
Unknown <sup>7</sup>	NA	<1%

NA = not applicable

1. See Table A. Genes and Databases for chromosome locus and protein.

2. See Molecular Genetics for information on variants detected in this gene.

3. Sequence analysis detects variants that are benign, likely benign, of uncertain significance, likely pathogenic, or pathogenic. Variants may include missense, nonsense, and splice site variants and small intragenic deletions/insertions; typically, exon or whole-gene deletions/duplications are not detected. For issues to consider in interpretation of sequence analysis results, click [here](#).

4. In individuals with severe (perinatal and infantile) hypophosphatasia, biallelic *ALPL* pathogenic variants are identified in approximately 95% of individuals of European ancestry. In other clinical phenotypes, the proportion of pathogenic variants detected is difficult to estimate.

5. Gene-targeted deletion/duplication analysis detects intragenic deletions or duplications. Methods used may include a range of techniques such as quantitative PCR, long-range PCR, multiplex ligation-dependent probe amplification (MLPA), and a gene-targeted microarray designed to detect single-exon deletions or duplications.

6. A few larger *ALPL* deletions and one duplication have been reported [Spentchian et al 2006, Hacihamdioglu et al 2019, Huggins et al 2020, Sperelakis-Beedham et al 2021, [The ALPL Gene Variant Database](#)].

7. Anecdotal reports of individuals with clinical and biochemical features of adult hypophosphatasia with no detected *ALPL* pathogenic variant(s) suggest a potential second locus, not yet identified.

## Clinical Characteristics

### Clinical Description

Hypophosphatasia is characterized by defective mineralization of bone and/or teeth and reduced serum alkaline phosphatase (ALP). The phenotypic spectrum ranges from stillbirth without mineralized bone at the severe end to pathologic stress fractures of the lower extremities in older adults at the mild end (Table 2). Intrafamilial clinical variability is common, particularly when some affected family members have a heterozygous *ALPL* pathogenic variant and other affected family members have biallelic pathogenic variants. Sibs with compound heterozygous variants tend to display less clinical variability at the severe end of the spectrum and more variability at the milder end of the spectrum.

**Table 2.** Select Clinical, Radiographic, and Laboratory Features of Hypophosphatasia by Type

Type	MOI	Cardinal Features	Additional Features
<b>Perinatal (severe)</b>	AR	<ul style="list-style-type: none"> <li>Hypomineralization</li> <li>Osteochondral spurs</li> </ul>	<ul style="list-style-type: none"> <li>Long bone bowing</li> <li>Pretibial dimpling</li> </ul>
<b>Perinatal (benign)</b>	AR/AD	<ul style="list-style-type: none"> <li>Long bone bowing</li> <li>Benign postnatal course</li> </ul>	
<b>Infantile</b>	Mostly AR	<ul style="list-style-type: none"> <li>Craniosynostosis</li> <li>Hypomineralization</li> <li>Rachitic ribs</li> <li>↑ serum calcium &amp; phosphorus</li> <li>Hypercalciuria</li> </ul>	<ul style="list-style-type: none"> <li>Additional clinical &amp; radiographic features of infantile rickets <sup>1, 2</sup></li> <li>Alveolar bone loss (anterior mandible)</li> <li>Premature loss of deciduous teeth</li> </ul>
<b>Severe childhood (juvenile)</b>	AR/AD	<ul style="list-style-type: none"> <li>Short stature</li> <li>Skeletal deformity</li> <li>Bone pain/fractures</li> <li>Focal metaphyseal defects resembling radiolucent "tongues"</li> </ul>	Premature loss of deciduous teeth (incisors)
<b>Mild childhood</b>	AR/AD	↑ fractures	Premature loss of deciduous teeth (incisors)

Table 2. continued from previous page.

Type	MOI	Cardinal Features	Additional Features
<b>Adult</b>	AR/AD	<ul style="list-style-type: none"> <li>• Stress fractures: metatarsal, tibia</li> <li>• Chondrocalcinosis</li> </ul>	<ul style="list-style-type: none"> <li>• Dental caries &amp; early loss or extraction of adult teeth</li> <li>• Osteopenia/osteoporosis</li> </ul>
<b>Odontohypophosphatasia</b>	AR/AD	Alveolar bone loss	<ul style="list-style-type: none"> <li>• Exfoliation (incisors)</li> <li>• Dental caries</li> </ul>

AD = autosomal dominant; AR = autosomal recessive; MOI = mode of inheritance

1. Clinical features of infantile rickets: growth failure, craniotabes, blue sclerae, scoliosis, thickening of wrists and ankles, bowing of lower extremities, lax ligaments, and hypotonia

2. Radiographic features of infantile rickets: widened-appearing sutures, brachycephaly, flail chest, flared metaphyses, poorly ossified epiphyses, and bowed long bones in the lower extremities

**Perinatal (severe) hypophosphatasia** is typically identified by prenatal ultrasound examination. Pregnancies may end in stillbirth. Small thoracic cavity and short, bowed limbs are seen in both stillborn and live-born infants. A flail chest may be present (see Figure 2A). Infants with perinatal hypophosphatasia may experience pulmonary insufficiency; restrictive lung disease is the most frequent cause of death. Hypercalcemia is common and may be associated with apnea or seizures. In those treated with asfotase alfa enzyme replacement therapy (ERT), a new phenotype of "treated perinatal and infantile hypophosphatasia" is emerging. However, even when the diagnosis is made expediently, unfavorable outcomes with ERT are possible [Duffus et al 2018]. Infants with perinatal (severe) hypophosphatasia started on ERT between age one day and age 78 months showed improvement in pulmonary function and survival. The effect of ERT on fractures remains unclear [Whyte et al 2019]. In the past, individuals with severe phenotypes died before dental eruption; emerging data suggest the possibility of dental features in infants treated with ERT.

**Perinatal (benign) hypophosphatasia** is typically identified by prenatal ultrasound examination showing short and bowed long bones but normal or slightly decreased mineralization. Postnatally, skeletal manifestations slowly resolve with a less severe hypophosphatasia phenotype [Wenkert et al 2011].

**Infantile hypophosphatasia.** There may be no clinical features apparent at birth. Clinical signs may be recognized between birth and age six months and resemble rickets (see Figure 2A). Clinical severity depends on the degree of pulmonary insufficiency; the infantile phenotype has high mortality. Prior to the availability of ERT, 50% of individuals succumbed to respiratory failure caused by undermineralization of the ribs. Other complications include hypercalcemia, irritability, poor feeding, failure to thrive, hypotonia, and more rarely vitamin B<sub>6</sub>-responsive seizures (see Management). Open fontanels and wide sutures may be deceptive, in that the hypomineralized bone causing this radiographic appearance is prone to premature fusion. Craniosynostosis and intracranial hypertension are potential complications. Older children may have kidney damage. Clinical trials with ERT have shown improvement in developmental milestones and pulmonary function (see Figure 3) [Whyte et al 2019].

**Severe childhood (juvenile) hypophosphatasia** displays wide variability in initial clinical presentation but often progresses to rickets. More severely affected toddlers have short stature and delay in walking, developing a waddling myopathic gait. Bone and joint pain are typical. Diaphyseal and metaphyseal fractures may occur. Gait, six-minute walk test, and step length improved in individuals treated with ERT. To date, data are insufficient to assess the effect of ERT on fractures in juvenile hypophosphatasia [Whyte et al 2016].

**Mild childhood hypophosphatasia** is characterized by low bone mineral density for age with unexplained fractures. Children may have premature loss of deciduous teeth (prior to age 5 years), usually beginning with incisors, with the dental root characteristically remaining attached to the lost tooth. Bone and joint pain are atypical.



**Adult hypophosphatasia** is sometimes associated with a history of transient rickets in childhood and/or premature loss of deciduous teeth. Early loss of adult dentition is common. Other dental problems in adolescents and adults with hypophosphatasia are more poorly characterized, although enamel hypoplasia and tooth mobility have been described. Adult hypophosphatasia is usually recognized in middle age, the cardinal features being stress fractures and pseudofractures of the lower extremities. Foot pain and slow-to-heal stress fractures of the metatarsals are common. Thigh and hip pain may reflect pseudofractures ("Looser zones") in the lateral cortex of the femoral diaphysis (see Figure 2D). Chondrocalcinosis and osteoarthropathy may develop with age (see Figure 4). Osteomalacia distinguishes adult hypophosphatasia from odontohypophosphatasia.

**Odontohypophosphatasia** can be seen as an isolated finding without additional abnormalities of the skeletal system or can be variably seen in the above forms of hypophosphatasia. Caution should be exercised in citing extradental manifestations of other forms of hypophosphatasia in individuals with odontohypophosphatasia, in that such features may be common and multifactorial (e.g., low bone density for age). Premature exfoliation of primary teeth and/or severe dental caries may be seen, with the incisors most frequently lost.

**Phenotype in those with heterozygous loss-of-function variants.** Heterozygous loss-of-function *ALPL* variants have been identified in adults with osteoporosis, musculoskeletal pain, and an increased risk of fractures [Mornet et al 2021]. These individuals are ascertained by low serum ALP and tend to have additional biochemical evidence of hypophosphatasia (elevated serum pyridoxal 5'-phosphate [PLP] or urine phosphoethanolamine [PEA]). Those ascertained as an incidental finding on molecular testing have lower ALP activity but may not display additional biochemical evidence. In this latter circumstance, elevated serum PLP or urine PEA may predict disease potential.

### Histopathology

- Bone histology reveals rachitic abnormalities of the growth plate. Histochemical testing of osteoclasts reveals lack of membrane-associated ALP activity. Osteoclasts and osteoblasts otherwise appear normal.
- Tooth histology reveals a decrease in cementum, which varies with the severity of the disease.

## Genotype-Phenotype Correlations

Most individuals with hypophosphatasia have unique *ALPL* variants, preventing the identification of genotype-phenotype correlations. However, site-directed mutagenesis experiments have identified variants producing significant residual enzymatic activity and variants with a dominant-negative effect (see Molecular Genetics).

Less severe phenotypes have been observed in individuals with biallelic loss-of-function variants that allow residual enzymatic activity or heterozygous variants exhibiting a dominant-negative effect [Fauvert et al 2009, Mornet et al 2021]. Clinical features of individuals with reported variants, as well as residual enzyme activity for some of those variants, can be found in the [ALPL Variants Database](#).

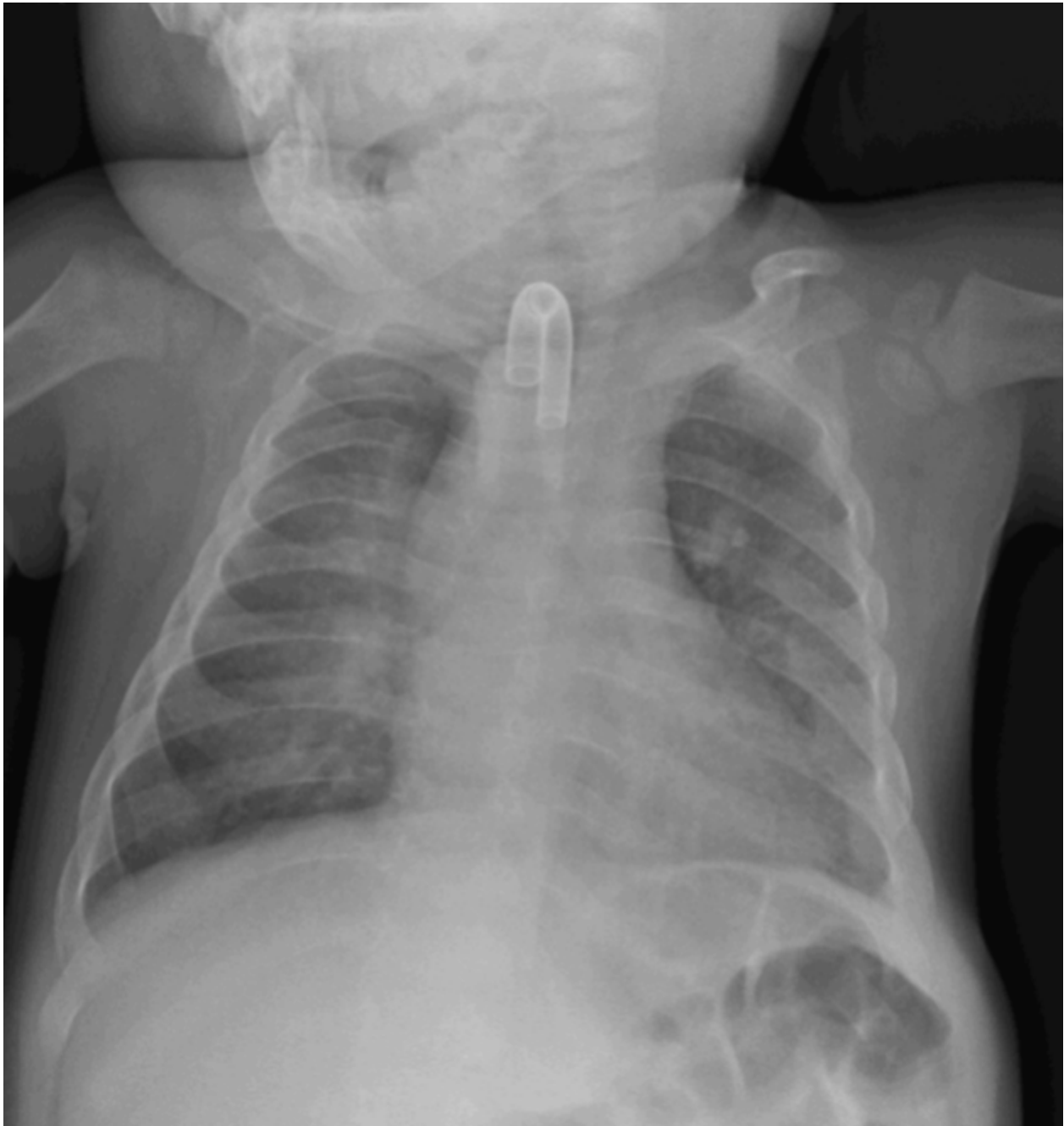## Penetrance

While some argue that penetrance is complete, reduced penetrance is possible in autosomal dominant hypophosphatasia due to *ALPL* variants manifesting a dominant-negative effect.

## Nomenclature

Hypophosphatasia takes its name from low activity of the enzyme ALP, rather than reflecting serum concentration of phosphorus.

In classifications of genetic conditions, hypophosphatasia may be considered a metabolic bone disease, a skeletal dysplasia, a metaphyseal dysplasia, a dental disorder, or a disorder of membrane-bound ectoenzyme activity in the extracellular matrix.

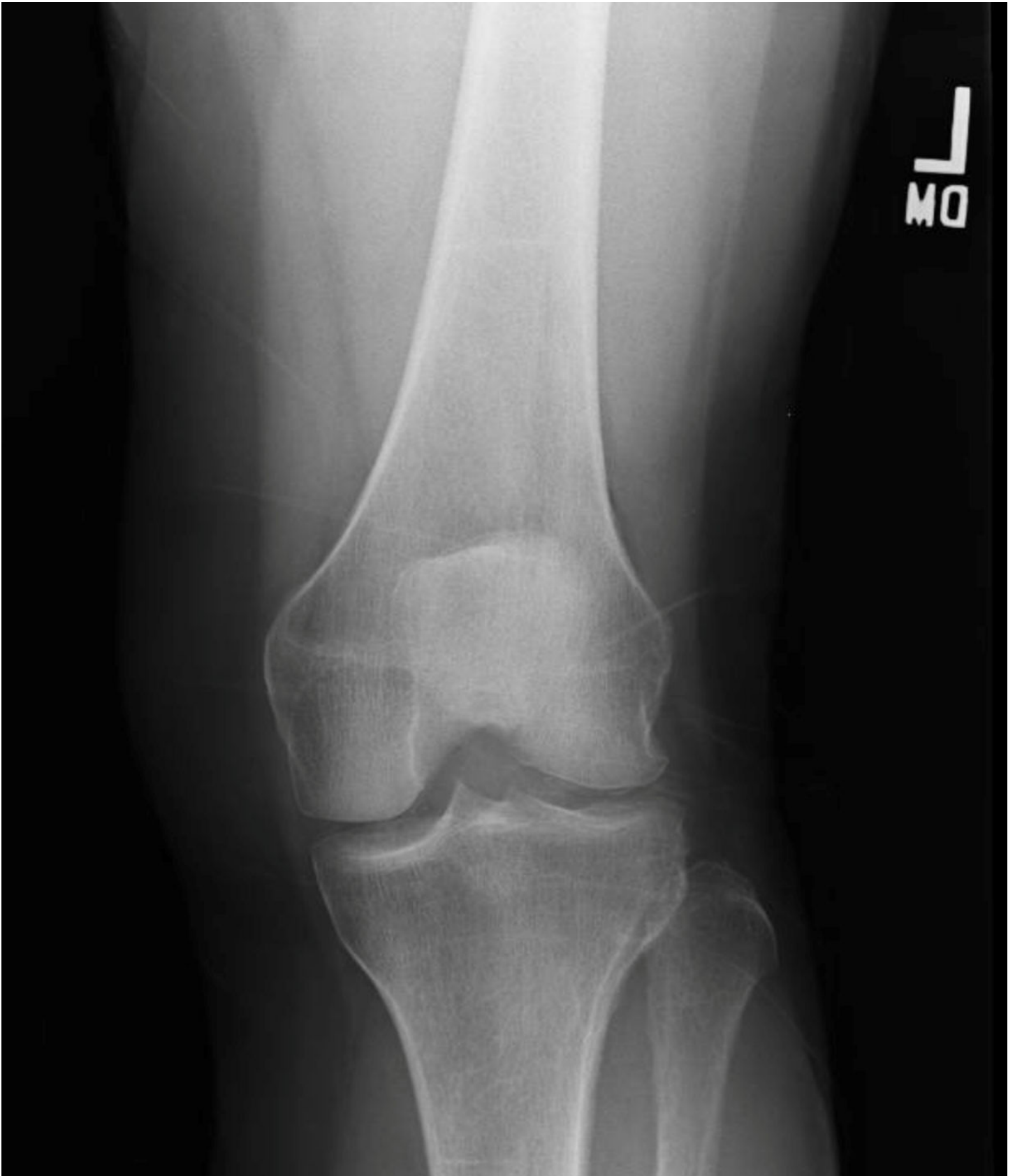

**Figure 3.** Radiograph of treated hypophosphatasia. Individual from Figure 2A after 12 months of asfotase alfa enzyme replacement therapy. Note tracheostomy tube, placed for laryngomalacia and bronchomalacia, features of the treated disease. Rachitic rib and metaphyseal changes have resolved. The two epiphyseal growth centers at the proximal humeri are normal.

## Prevalence

Based on pediatric hospital records in Ontario, Canada, the birth prevalence of (autosomal recessive) perinatal and infantile hypophosphatasia was estimated at 1:100,000 [Fraser 1957]. Applying the Hardy-Weinberg equation to this estimate, the frequency of heterozygotes for *ALPL* pathogenic variants in Ontario, Canada, is about 1:150.

In the Canadian Mennonite population, the prevalence of the perinatal (severe) form is 1:2,500 (carrier frequency 1:25) due to founder the variant p.Gly334Asp [Triggs-Raine et al 2016].



**Figure 4.** Radiograph of treated adult hypophosphatasia: linear sclerosis in remodeling distal femur and proximal tibia, osteophytes mid-proximal tibia, and chondrocalcinosis medial lateral compartment

On the basis of molecular diagnosis in France and elsewhere in Europe, the prevalence of severe forms has been estimated at 1:300,000. For mild forms (perinatal benign, mild childhood, adult, and odontohypophosphatasia), the prevalence is expected to be as high as 1:6,300 [Mornet et al 2011] because heterozygotes may express the disease with low selective pressure. Applying the Hardy-Weinberg equation to this estimate for severe forms, the frequency of heterozygotes for *ALPL* pathogenic variants in France is about 1:275.

In Japan, the birth prevalence of severe hypophosphatasia may be estimated at 1:150,000 on the basis on the frequency of individuals homozygous for the pathogenic variant c.1559delT (1:900,000 [Watanabe et al 2011]) and on the proportion of this pathogenic variant in affected individuals of Japanese ancestry (45.4% [Michigami et al 2020]).

In China, some pathogenic variants have been reported [Wei et al 2010, Zhang et al 2012, Yang et al 2013] but the birth prevalence is unknown.

In Africa, no individuals with hypophosphatasia have been reported in the medical literature outside of North Africa and South Africa; however, clinical ascertainment bias is significant. African American individuals with hypophosphatasia are rare; it is assumed that pathogenic variants in this population represent European admixture.

## Genetically Related (Allelic) Disorders

No phenotypes other than those discussed in this *GeneReview* are known to be associated with germline pathogenic variants in *ALPL*.

## Differential Diagnosis

The differential diagnosis of hypophosphatasia depends on the age at which the diagnosis is considered. Clinical features that help differentiate hypophosphatasia from other conditions include bone hypomineralization prenatally and immediately postnatally; elevated serum concentrations of calcium and phosphorus postnatally; and persistently low serum alkaline phosphatase (ALP) enzyme activity.

### In Utero

Early prenatal ultrasound examination may lead to a consideration of *osteogenesis imperfecta* (OI) type II, *campomelic dysplasia*, and chondrodysplasias with defects in bone mineralization, as well as hypophosphatasia. Experienced sonographers usually have little difficulty in distinguishing among these disorders. Fetal radiographs are sometimes helpful in recognizing the undermineralization of bone that is more typical of perinatal hypophosphatasia than of the other disorders considered in the differential diagnosis.

### At Birth

Outwardly difficult to distinguish, OI type II, *thanatophoric dysplasia*, campomelic dysplasia, and chondrodysplasias with bone mineralization defects are readily distinguished from hypophosphatasia by radiograph. In individuals in which the diagnosis is in doubt, analysis of serum ALP activity, pyridoxal 5'-phosphate (PLP) or vitamin B<sub>6</sub>, and urine phosphoethanolamine (PEA) can suggest the diagnosis pending confirmation with molecular genetic testing.

## Infancy and Childhood

Irritability, poor feeding, failure to thrive, hypotonia, and seizures place the **infantile type** in a broad differential diagnosis that includes inborn errors of energy metabolism, organic acidemia, primary and secondary rickets, neglect, and non-accidental trauma. **Infantile hypophosphatasia** is suspected with low serum ALP enzyme

activity, making the argument for routine screening of serum ALP enzyme activity in infants and children with failure to thrive, unexplained seizures, and suspected non-accidental skeletal injury.

**Table 3.** Acquired Disorders and Disorders of Unknown Cause in the Differential Diagnosis of Infantile and Childhood-Onset Hypophosphatasia

Disorder	Clinical Features / Comment
<b>Intractable seizures</b>	May present prior to biochemical or radiographic manifestations of rickets in early hypophosphatasia
<b>Rickets</b>	The clinical & radiographic features of rickets are present in perinatal & infantile presentations of hypophosphatasia. However, rickets caused by nutritional &/or vitamin D deficiency, vitamin D resistance, or renal osteodystrophy are readily distinguished from hypophosphatasia by lab findings. In these causes of rickets, the following are characteristic: <ul style="list-style-type: none"> <li>• ↑ serum alkaline phosphatase activity</li> <li>• Low serum calcium &amp; phosphorus</li> <li>• Low serum vitamin D</li> <li>• ↑ serum parathyroid hormone</li> </ul>
<b>Idiopathic juvenile osteoporosis</b>	Typically presents in preadolescents w/fractures & osteoporosis. The fracture susceptibility & osteoporosis usually resolve spontaneously w/puberty.
<b>Renal osteodystrophy</b>	May be confused w/late presentation of the childhood (juvenile) type assoc w/kidney damage; however, characteristic biochemical findings distinguish the disorders.
<b>Non-accidental trauma (child abuse)</b>	Like OI, medical history, family history, physical exam, routine lab tests, radiographic imaging, & clinical course all contribute to distinguishing hypophosphatasia from child abuse. Multiple fractures are less typical of hypophosphatasia. Family history may be particularly instructive: the perinatal (severe) type is AR, & childhood (juvenile), adult, & odontohypophosphatasia types are AD; all have been reported in a single family ascertained by unexplained fracture in a child. <sup>1</sup> Serial measurement of serum ALP activity is usually sufficient to identify hypophosphatasia in this circumstance.
<b>Pseudohypophosphatasia</b>	Characterized by clinical, biochemical, & radiographic findings reminiscent of infantile hypophosphatasia, w/exception that clinical lab assays of serum ALP activity are in normal range.
<b>Periodontal disease</b>	In advanced, Stage V periodontitis, loss of mandibular bone may → tooth loss w/intact root. This is unusual prior to adulthood.

AD = autosomal dominant; ALP = alkaline phosphatase; AR = autosomal recessive; OI = osteogenesis imperfecta

1. Lia-Baldini et al [2001]

**Table 4.** Hereditary Disorders in the Differential Diagnosis of Infantile and Childhood-Onset Hypophosphatasia

Gene	Disorder	MOI	Clinical Features / Comment
<i>COL1A1</i> <i>COL1A2</i> <sup>1</sup>	Osteogenesis imperfect (OI) (See <i>COL1A1/2 Osteogenesis Imperfecta</i> .)	AD	OI w/deformation (typically type III in infancy or type IV later on) may resemble hypophosphatasia clinically.
<i>DSPP</i>	Dentinogenesis imperfect (OMIM <i>DSPP Clinical Synopsis</i> )	AD	Whether part of OI or an isolated finding, dentinogenesis imperfecta is distinguishable from dental presentation of hypophosphatasia.
<i>LIFR</i>	Stuve-Wiedemann syndrome (OMIM 601559)	AR	Presents w/temperature dysregulation, diminished reflexes, & contractures, but severe perinatal presentation shares several features w/hypophosphatasia: respiratory insufficiency, bowing of long bones, metaphyseal dysplasia, low bone density for age, & fracture predilection.

Table 4. continued from previous page.

Gene	Disorder	MOI	Clinical Features / Comment
<i>NOTCH2</i>	Hadju-Cheney syndrome (OMIM 102500)	AD	Characterized by failure to thrive, dysmorphic facial features, early tooth loss, genitourinary anomalies, osteopenia, pathologic fractures, wormian bones, failure of suture ossification, basilar impression, vertebral abnormalities, joint laxity, bowed fibulae, short distal digits, acroosteolysis, & hirsutism
<i>P4HB</i> <i>SEC24D</i>	Cole-Carpenter syndrome (OMIM PS112240)	AD AR	Characterized by bone deformities, multiple fractures, proptosis, shallow orbits, orbital craniosynostosis, frontal bossing, & hydrocephalus
<i>RUNX2</i>	Cleidocranial dysplasia spectrum disorder	AD	Characterized by late closure of fontanels & cranial sutures, aplastic clavicles, delayed mineralization of the pubic rami, & delayed eruption of deciduous & permanent teeth. Skeletal dysplasia is distinguishable from hypophosphatasia on clinical exam & skeletal survey. Dental dysplasia does not result in early tooth loss, & enamel hypoplasia is readily distinguishable from odontohypophosphatasia.

AD = autosomal dominant; AR = autosomal recessive; MOI = mode of inheritance

1. For additional genes associated with OI, see [COL1A1/2 Osteogenesis Imperfecta](#), Table 5.

## Adult and Odontohypophosphatasia

**Table 5.** Acquired Disorders and Disorders of Unknown Cause in the Differential Diagnosis of Adult-Onset Hypophosphatasia and Odontohypophosphatasia

Disorder	Clinical Features / Comment
<b>Osteoarthritis &amp; pseudogout</b> (secondary to calcium pyrophosphate dehydrate deposition)	Both are presentations of adult hypophosphatasia, distinguished from the more common disorders by clinical history & lab findings.
<b>Osteopenia/osteoporosis</b>	Must be distinguished from adult hypophosphatasia, in that bisphosphonates may be contraindicated (See Management, Agents/Circumstances to Avoid.)
<b>Periodontal disease</b>	May be difficult to distinguish from hypophosphatasia, in that alveolar bone loss can be seen w/severe gingivitis. However, gingival inflammation is unusual w/odontohypophosphatasia.
<b>Adult pseudohypophosphatasia</b>	Characterized by clinical, biochemical, & radiographic findings reminiscent of adult hypophosphatasia, w/exception that clinical lab assays of serum ALP activity are in normal range.

ALP = alkaline phosphatase

**Table 6.** Hereditary Disorders in the Differential Diagnosis of Adult-Onset Hypophosphatasia and Odontohypophosphatasia

Gene	Disorder	MOI	Clinical Features / Comment
<i>C1R</i> <i>C1S</i> <i>COL3A1</i>	Familial periodontal disease as part of connective tissue disorder (e.g., <a href="#">vascular Ehlers-Danlos syndrome [EDS]</a> or <a href="#">periodontal EDS</a> )	AD (AR <sup>1</sup> )	Periodontal EDS may present w/root-intact tooth loss, the distinction being low serum ALP in odontohypophosphatasia.
<i>CTSC</i>	Aggressive periodontitis 1 (OMIM 170650)	AR	Familial periodontal disease
	Papillon-Lefevre syndrome (OMIM 245000)	AR	Rarer disorders assoc w/premature tooth loss & periodontal disease. The periodontal disease is usually earlier in onset & more severe than that seen w/odontohypophosphatasia. Both Papillon-Lefevre syndrome & HMS are usually assoc w/palmar keratosis, further distinguishing them from odontohypophosphatasia. Measurement of serum ALP enzyme activity is reasonable when either disorder is considered.
	Haim-Munk syndrome (HMS) (OMIM 245010)	AR	



Table 6. continued from previous page.

Gene	Disorder	MOI	Clinical Features / Comment
<i>DSPP</i>	Dentinogenesis imperfecta (OMIM <a href="#">DSPP Clinical Synopsis</a> )	AD	Dentinogenesis imperfecta is readily distinguishable from odontohypophosphatasia on biochemical findings.
<i>ELANE</i>	Familial periodontal disease assoc w/neutropenia (e.g., <a href="#">ELANE-related neutropenia</a> )	AD	<i>ELANE</i> -related neutropenia includes congenital neutropenia & cyclic neutropenia, both of which are primary hematologic disorders characterized by recurrent fever, skin & oropharyngeal inflammation (e.g., mouth ulcers, gingivitis, sinusitis, & pharyngitis), & cervical adenopathy.

AD = autosomal dominant; ALP = alkaline phosphatase; AR = autosomal recessive; MOI = mode of inheritance

1. Vascular EDS is almost always inherited in an autosomal dominant manner, but rare examples of biallelic inheritance have been reported.

## Management

### Evaluations Following Initial Diagnosis

To establish the extent of disease and needs in an individual diagnosed with hypophosphatasia, the evaluations summarized in Table 7 and Table 8 (if not performed as part of the evaluation that led to the diagnosis) are recommended.

**Table 7.** Recommended Evaluations Following Initial Diagnosis in Infants with Perinatal Hypophosphatasia

System/Concern	Evaluation	Comment
<b>Calcium homeostasis</b>	<ul style="list-style-type: none"> <li>Serum calcium, phosphorus, magnesium</li> <li>Referral to endocrinologist for mgmt of bone health</li> </ul>	To identify those at risk of apnea &/or seizures due to hypercalcemia
<b>Pulmonary insufficiency</b>	Clinical assessment of pulmonary function	To assist in prognosis & distinguishing between severe & benign perinatal types
<b>Orthopedic manifestations</b>	<ul style="list-style-type: none"> <li>Orthopedic eval</li> <li>Skeletal survey incl radiographs of skull to assess for craniosynostosis</li> </ul>	
<b>Seizures</b>	Eval by neurologist for suspected seizures	
<b>Craniosynostosis</b>	Eval by craniofacial specialists &/or neurosurgeon for those w/ craniosynostosis	
<b>Renal function</b>	<ul style="list-style-type: none"> <li>Blood urea nitrogen &amp; serum creatinine concentration</li> <li>Referral to nephrologist</li> </ul>	
<b>Family support &amp; resources</b>	Assess need for: <ul style="list-style-type: none"> <li>Community or online resources such as <a href="#">Parent to Parent</a>;</li> <li>Social work involvement for parental support;</li> <li>Home nursing referral.</li> </ul>	
<b>Genetic counseling</b>	By genetics professionals <sup>1</sup>	To inform affected persons & families re nature, MOI, & implications of hypophosphatasia to facilitate medical & personal decision making

MOI = mode of inheritance

1. Medical geneticist, certified genetic counselor, certified advanced genetic nurse



**Table 8.** Recommended Evaluations Following Initial Diagnosis in Older Individuals with Hypophosphatasia

System/Concern	Evaluation	Comment
<b>Orthopedic manifestations</b>	<ul style="list-style-type: none"> <li>Orthopedic eval</li> <li>Skeletal survey incl radiographs of skull to assess for craniosynostosis</li> </ul>	If head shape is abnormal, consider 3D CT scan to further evaluate craniosynostosis.
<b>Calcium homeostasis</b>	<ul style="list-style-type: none"> <li>Serum 25-hydroxy vitamin D, 1,25-dihydroxy vitamin D, &amp; nPTH to assess for confounding comorbidity (e.g., vitamin D deficiency)</li> <li>Referral to endocrinologist for mgmt of bone health</li> </ul>	
<b>Renal function</b>	<ul style="list-style-type: none"> <li>Blood urea nitrogen &amp; serum creatinine concentration</li> <li>Referral to nephrologist</li> </ul>	
<b>Dental complications</b>	Dental eval	By age 1 yr
<b>Genetic counseling</b>	By genetics professionals <sup>1</sup>	To inform affected persons & families re nature, MOI, & implications of hypophosphatasia to facilitate medical & personal decision making

MOI = mode of inheritance; nPTH = parathyroid hormone, N-terminal part

1. Medical geneticist, certified genetic counselor, certified advanced genetic nurse

## Treatment of Manifestations

There is no cure for hypophosphatasia. Targeted therapy in the form of enzyme replacement therapy (ERT) is available, and supportive care by specialists is recommended.

### Targeted Therapy

*In GeneReviews, a targeted therapy is one that addresses the specific underlying mechanism of disease causation (regardless of whether the therapy is significantly efficacious for one or more manifestation of the genetic condition); would otherwise not be considered without knowledge of the underlying genetic cause of the condition; or could lead to a cure. —ED*

Asfotase alfa (Strensiq®) ERT has been shown to improve pulmonary function, calcium homeostasis / bone health, and survival in individuals with the infantile and early childhood (juvenile) type of hypophosphatasia. There is growing experience with ERT in individuals with the perinatal (severe) type and emerging experience with ERT in treating osteomalacia in adults.

**Table 9.** Targeted Treatment of Hypophosphatasia

Targeted Treatment	Dosage	Considerations
Asfotase alfa ERT <sup>1, 2</sup>	<p>Asfotase alfa ERT is given as a subcutaneous injection.</p> <ul style="list-style-type: none"> <li>Infants: total dose ≤9 mg/kg per week</li> <li>Adolescents &amp; adults: total dose of 6 mg/kg per week</li> </ul>	<ul style="list-style-type: none"> <li>The most common regimens are a 1 mg/kg injection 6x per week or a 2 mg/kg injection 3x per week.</li> <li>In absence of ERT, calcitonin &amp; steroids could be attempted short term; efficacy is limited. <sup>3</sup></li> </ul>

ERT = enzyme replacement therapy

1. The treatment duration and long-term effects of ERT with asfotase alfa remain unknown for perinatal and infantile hypophosphatasia. In theory, ERT would be less effective once endochondral bone formation is complete after the epiphyses fuse.

2. Clinical trials in adults are limited to those with documented childhood disease, and in theory the treatment has occurred after endochondral bone formation is complete (remodeling phase). Biochemical and limited functional improvement can be documented, but treatment end points, duration, and long-term effects are unknown for adult hypophosphatasia.

3. Deeb et al [2000]

## Supportive Care

At all ages, supportive care to improve quality of life, maximize function, and reduce complications is recommended. This ideally involves multidisciplinary care by specialists in relevant fields (see Table 10).

**Table 10.** Treatment of Manifestations in Individuals with Hypophosphatasia

Manifestation/Concern	Treatment	Considerations/Other
<b>Respiratory compromise</b>	<ul style="list-style-type: none"> <li>Respiratory support per pulmonologist</li> <li>Asfotase alfa ERT (see Table 9) has been shown to improve survival &amp; pulmonary function.</li> </ul>	Comfort care & supportive mgmt of infants w/ perinatal (severe) type remains an option for those w/o access to ERT.
<b>Calcium homeostasis / Bone health</b>	Mgmt per endocrinologist to optimize bone homeostasis & avoid exacerbating treatments	Mgmt of calcium homeostasis can further be complicated by recalcitrant hypercalcemia/ hypercalciuria, & optimal mgmt remains unclear: hypercalcemia/ hypercalciuria is typically resistant to hydration & furosemide treatment, & bisphosphonates would be contraindicated (see Agents/Circumstances to Avoid).
	Asfotase alfa ERT (See Table 9.)	
	<ul style="list-style-type: none"> <li>Physical medicine &amp; rehab, PT, &amp; OT to optimize mobility &amp; autonomy</li> <li>Low-impact physical activity &amp; exercise</li> </ul>	Supervision by physician specialist familiar w/ hypophosphatasia is suggested.
	Adults: calcium & vitamin D supplementation may prevent secondary hyperparathyroidism.	This should only be pursued w/close monitoring by physician specialist familiar w/hypophosphatasia.
<b>Fractures</b>	<ul style="list-style-type: none"> <li>Mgmt of primary &amp; secondary skeletal manifestations per orthopedist</li> <li>Internal fixation has been suggested as optimal mgmt.</li> <li>Consider foot orthotics for tarsal fractures &amp; pseudofractures in adults.</li> </ul>	Pseudofractures & stress fractures are difficult to manage.
<b>Bone pain &amp; osteomalacia</b>	Adults: Teriparatide may improve pain, mobility, & fracture repair. <sup>1</sup>	<ul style="list-style-type: none"> <li>Teriparatide ↑s production of TNSALP in osteoblasts. To date, there are no prospective studies or clinical trials. Improvement in biochemical markers &amp; bone mineral density have been mixed. <sup>2</sup></li> <li>Teriparatide is contraindicated in children (see Agents/Circumstances to Avoid).</li> </ul>
	<ul style="list-style-type: none"> <li>Pain mgmt</li> <li>NSAIDs</li> </ul>	Bisphosphonates are contraindicated (see Agents/Circumstances to Avoid).
<b>Osteoarthritis</b>	May respond to NSAIDs	
<b>Craniosynostosis</b>	Mgmt per neurosurgeon to monitor & manage complications incl: <ul style="list-style-type: none"> <li>Intracranial hypertension</li> <li>Indication for surgical release</li> </ul>	Craniosynostosis in those w/infantile type is variable.
<b>Kidney disease</b>	Mgmt per nephrologist to monitor calcium homeostasis & assess for nephrocalcinosis	

Table 10. continued from previous page.

Manifestation/Concern	Treatment	Considerations/Other
<b>Seizures &amp; myopathy</b>	<ul style="list-style-type: none"> <li>Mgmt per neurologist to prophylactically or prospectively treat seizures &amp; manage myopathy</li> <li>Seizures may respond to treatment w/vitamin B<sub>6</sub> (pyridoxine).</li> </ul>	PLP is one of the natural substrates of ALP; PLP deficiency in CNS may ↓ seizure threshold by ↓ing neurotransmitter synthesis.
<b>Dental complications</b>	Pediatric & adult dentistry to preserve primary dentition (to support nutrition) & to preserve or replace secondary dentition.	By age 1 yr
<b>Family support &amp; resources</b>	Psychological support & social work support	The involvement of multiple specialists treating complex interrelated medical issues mandates case mgmt & social work support.

ALP = alkaline phosphatase; CNS = central nervous system; ERT = enzyme replacement therapy; NSAIDs = nonsteroidal anti-inflammatory drugs; OT = occupational therapy; PLP = pyridoxal phosphate; PT = physical therapy; TNSALP = alkaline phosphatase, tissue-nonspecific isozyme

1. Schalin-Jääntti et al [2010]

2. Camacho et al [2016]

## Surveillance

Table 11. Recommended Surveillance for Individuals with Hypophosphatasia

System/Concern	Evaluation	Frequency
<b>Calcium homeostasis / Bone health</b>	Endocrinology &/or nephrology follow up	Per endocrinologist or nephrologist
	Physical medicine & rehab, PT, & OT	As needed
	Orthopedic follow up	Per orthopedist
<b>Craniosynostosis</b>	Neurosurgery follow up to monitor for ↑ intracranial pressure secondary to craniosynostosis in infantile type	Per neurosurgeon
<b>Kidney disease</b>	Nephrology follow up	Per nephrologist
<b>Seizures</b>	Neurology eval	As needed
<b>Dental complications</b>	Pediatric dental eval	Every 6 mos beginning at age 1 yr

OT = occupational therapy; PT = physical therapy

## Agents/Circumstances to Avoid

**Bisphosphonates** are relatively contraindicated in hypophosphatasia. Although adverse outcomes have not been identified in children with the infantile type [Deeb et al 2000], theoretic concern has long been raised based on the structure of bisphosphonates. The phosphate motifs in bisphosphonates have a similar conformation to inorganic pyrophosphate (PPi), the natural substrate of TNSALP (alkaline phosphatase, tissue-nonspecific isozyme); thus, treatment with bisphosphonates is thought to be analogous to "adding fuel to the fire." In adults with hypophosphatasia and osteomalacia treated with bisphosphonates, lateral subtrochanteric femoral pseudofractures have been described [Whyte 2009]. As the prevalence of adult hypophosphatasia is not known and many undiagnosed adults undoubtedly are treated with bisphosphonates, the frequency of this unusual complication is not known.

**Excess vitamin D** can exacerbate hypercalcemia/hypercalciuria in children with infantile hypophosphatasia who have hypercalcemia.

**Teriparatide** (recombinant human parathyroid hormone fragment, amino acids 1-34) at high doses induces osteosarcoma in rats and may increase the risk of radiation-induced osteosarcoma (a pediatric growth plate tumor) in humans. Thus, it is contraindicated in children with hypophosphatasia.

## Evaluation of Relatives at Risk

It is appropriate to clarify the genetic status of apparently asymptomatic older and younger at-risk relatives of an affected individual in order to identify as early as possible those who would benefit from prompt initiation of treatment and preventive measures.

See Genetic Counseling for issues related to testing of at-risk relatives for genetic counseling purposes.

## Pregnancy Management

The use of asfotase alfa (Strensiq<sup>®</sup>) ERT during human pregnancy has not been extensively studied; therefore, any potential risk to the fetus of a pregnant woman taking this therapy during pregnancy is unknown.

See [MotherToBaby](#) for further information on medication use during pregnancy.

## Therapies Under Investigation

**Osteoblast enhancement by anti-sclerostin antibodies.** Teriparatide enhances osteoblast production of TNSALP, and sclerostin inhibits osteoblast differentiation. Anti-sclerostin therapies have emerged for metabolic bone diseases. A specific Phase II clinical open-label trial for eight adults with hypophosphatasia (mean age 47.8 years) using anti-sclerostin monoclonal antibodies (BPS804) showed early improvement in bone density and markers of bone turnover in seven individuals completing the 16-week study period. Hypophosphatasia-specific biomarkers other than serum alkaline phosphatase were not reported, and functional assessments were beyond the scope of a Phase II study [Seefried et al 2017].

**Bone marrow transplantation** (hematopoietic cell transplantation) was used to treat an eight-month-old girl with severe hypophosphatasia with prolonged, significant clinical and radiologic improvement [Whyte et al 2003]. Seven years after transplantation, she was reported to be active and growing, and to have the clinical phenotype of the childhood (juvenile) form of hypophosphatasia [Cahill et al 2007]. In another trial, both bone marrow and allogenic mesenchymal stem cells were implanted in an eight-month-old infant, resulting in improvement of respiratory conditions [Tadokoro et al 2009]. However, the infant developed therapy-related leukemia [Taketani et al 2013]. Transplantation of ex vivo expanded mesenchymal stem cells for individuals who had previously undergone bone marrow transplantation improved bone mineralization, muscle mass, respiratory function, intellectual development, and survival [Taketani et al 2015].

Search [ClinicalTrials.gov](#) in the US and [EU Clinical Trials Register](#) in Europe for access to information on clinical studies for a wide range of diseases and conditions.

## Genetic Counseling

*Genetic counseling is the process of providing individuals and families with information on the nature, mode(s) of inheritance, and implications of genetic disorders to help them make informed medical and personal decisions. The following section deals with genetic risk assessment and the use of family history and genetic testing to clarify genetic status for family members; it is not meant to address all personal, cultural, or ethical issues that may arise or to substitute for consultation with a genetics professional. —ED.*

## Mode of Inheritance

Perinatal and infantile hypophosphatasia are typically inherited in an autosomal recessive manner.

Milder forms of hypophosphatasia, especially adult and odontohypophosphatasia, may be inherited in an autosomal recessive or autosomal dominant manner depending on the effect of the *ALPL* pathogenic variant on TNSALP (alkaline phosphatase, tissue-nonspecific isozyme) activity [Mornet et al 2021]. *ALPL* variants with a dominant-negative effect are associated with autosomal dominant inheritance.

Intrafamilial clinical variability is common, particularly when some affected family members have a heterozygous *ALPL* pathogenic variant and other affected family members have biallelic pathogenic variants. Individuals with severe perinatal, childhood, and adult forms of hypophosphatasia may be seen in families segregating two *ALPL* pathogenic variants.

Reliable assessment of recurrence risk requires identification of the causative pathogenic variant(s) in the proband and molecular genetic testing of the proband's parents to confirm their genetic status.

## Autosomal Recessive Inheritance (Proband with Biallelic Pathogenic Variants) – Risk to Family Members

### Parents of a proband

- The parents of a child with biallelic *ALPL* pathogenic variants are typically heterozygous for one *ALPL* pathogenic variant.
- Molecular genetic testing is recommended for the parents of a proband to confirm that both parents are heterozygous for an *ALPL* pathogenic variant and to allow reliable recurrence risk assessment.
- If a pathogenic variant is detected in only one parent and parental identity testing has confirmed biological maternity and paternity, it is possible that one of the pathogenic variants identified in the proband occurred as a *de novo* event in the proband [Taillandier et al 2005, Zhang et al 2012] or as a postzygotic *de novo* event in a mosaic parent. If the proband appears to have homozygous pathogenic variants (i.e., the same two pathogenic variants), additional possibilities to consider include:
  - A single- or multiexon deletion in the proband that was not detected by sequence analysis and that resulted in the artifactual appearance of homozygosity;
  - Uniparental isodisomy for the parental chromosome with the pathogenic variant that resulted in homozygosity for the pathogenic variant in the proband [Watanabe et al 2014, Hancarova et al 2015].
- Depending on the *ALPL* pathogenic variant, heterozygous parents are either clinically asymptomatic (manifesting only biochemical abnormality) or have milder clinical symptoms than their child (see Molecular Pathogenesis).

### Sibs of a proband

- If both parents are known to be heterozygous for an *ALPL* pathogenic variant, each sib of an affected individual has at conception a 25% chance of inheriting biallelic pathogenic variants, a 50% chance of being heterozygous, and a 25% chance of inheriting neither of the familial pathogenic variants.
- Sibs who inherit biallelic pathogenic variants tend to have similar disease severity; however, growth differences, nutrition, activity level, and earlier age of diagnosis all may influence phenotype. Sibs with compound heterozygous variants tend to display less intrafamilial clinical variability at the severe end of the spectrum and more variability at the milder end of the spectrum.
- Depending on the *ALPL* pathogenic variant, heterozygous sibs may be either clinically asymptomatic (manifesting only biochemical abnormality) or have milder clinical symptoms than the proband (see Molecular Pathogenesis).

**Offspring of a proband.** Unless an individual with autosomal recessive hypophosphatasia has children with an affected individual or a heterozygote, offspring will be obligate heterozygotes for a pathogenic variant in *ALPL*.

Note: In the Canadian Mennonite population, the prevalence of the perinatal (severe) form is 1:2,500, with a carrier frequency of 1:25, due to a founder variant (see Prevalence).

**Other family members.** Each sib of the proband's parents is at a 50% risk of being heterozygous for a pathogenic variant in *ALPL*.

## Heterozygote Detection

Heterozygote testing for at-risk relatives requires prior identification of the *ALPL* pathogenic variants in the family.

## Autosomal Dominant Inheritance (Proband with a Heterozygous *ALPL* Variant with a Dominant-Negative Effect) – Risk to Family Members

### Parents of a proband

- All individuals reported to date with hypophosphatasia caused by a heterozygous *ALPL* variant with a dominant-negative effect inherited the *ALPL* pathogenic variant from a parent (who may or may not have clinical manifestations of hypophosphatasia).
- Recommendations for the evaluation of parents of a proband include review of clinical history and laboratory evaluations for signs of hypophosphatasia. Molecular genetic testing is recommended for the parents of the proband to confirm their genetic status and to allow reliable recurrence risk counseling.
- If the pathogenic variant identified in the proband is not identified in either parent and parental identity testing has confirmed biological maternity and paternity, the following possibilities should be considered:
  - The proband has a *de novo* pathogenic variant.
  - The proband inherited a pathogenic variant from a parent with germline (or somatic and germline) mosaicism. Note: Testing of parental leukocyte DNA may not detect all instances of somatic mosaicism and will not detect a pathogenic variant that is present in the germ cells only.
- Evaluation of parents may determine that a parent is affected but has escaped previous diagnosis because of failure by health care professionals to recognize the disorder, reduced penetrance, and/or a milder phenotypic presentation. Therefore, an apparently negative family history cannot be confirmed unless molecular genetic testing has demonstrated that neither parent is heterozygous for the *ALPL* pathogenic variant identified in the proband.

**Sibs of a proband.** The risk to the sibs of the proband depends on the genetic status of the proband's parents:

- If a parent of the proband is known to have the pathogenic variant identified in the proband, the risk to the sibs of inheriting the pathogenic variant is 50%.
- Clinical severity is often similar in affected family members but cannot be reliably predicted by family history or molecular genetic testing due to reduced penetrance and variable expressivity.
- If the *ALPL* pathogenic variant identified in the proband cannot be detected in the leukocyte DNA of either parent, the recurrence risk to sibs is estimated to be 1% because of the theoretic possibility of parental germline mosaicism [Rahbari et al 2016].

**Offspring of a proband.** Each child of an individual with a heterozygous *ALPL* pathogenic variant has a 50% chance of inheriting the pathogenic variant.

**Other family members.** The risk to other family members depends on the status of the proband's parents: if a parent has an *ALPL* pathogenic variant, the parent's family members may be at risk.



## Related Genetic Counseling Issues

See Management, Evaluation of Relatives at Risk for information on evaluating at-risk relatives for the purpose of early diagnosis and treatment.

### Family planning

- The optimal time for determination of genetic risk and discussion of the availability of prenatal/preimplantation genetic testing is before pregnancy.
- It is appropriate to offer genetic counseling (including discussion of potential risks to offspring and reproductive options) to young adults who are affected, are heterozygous, or are at risk of being heterozygous.

**DNA banking.** Because it is likely that testing methodology and our understanding of genes, pathogenic mechanisms, and diseases will improve in the future, consideration should be given to banking DNA from probands in whom a molecular diagnosis has not been confirmed (i.e., the causative pathogenic mechanism is unknown). For more information, see Huang et al [2022].

## Prenatal Testing and Preimplantation Genetic Testing

### Pregnancy with high a priori risk (pregnancy known to be at increased risk based on family history)

- **Molecular genetic testing.** Once the *ALPL* pathogenic variant(s) have been identified in an affected family member, prenatal testing and preimplantation genetic testing for hypophosphatasia are possible.
- **Fetal ultrasonography.** Recurrence of perinatal hypophosphatasia may reliably be identified by prenatal ultrasound examination. Undermineralization, small thoracic cavity, shortened long bones, and bowing are typical features of autosomal recessive and severe hypophosphatasia. Long bone bowing has been reported prenatally in affected sibs and in children of individuals with childhood (juvenile) or adult hypophosphatasia, but the finding is not diagnostic of perinatal severe hypophosphatasia, since it may also be seen in perinatal benign hypophosphatasia, a clinical form that can improve during later stages of pregnancy and result in nonlethal hypophosphatasia [Wenkert et al 2011]. Established information on the functional effect of some *ALPL* pathogenic variants can assist in distinguishing lethal and nonlethal hypophosphatasia prenatally [Sperelakis-Beedham et al 2021].
- **Biochemical testing.** Concentration of alkaline phosphatase in amniotic fluid, amniocytes, and chorionic villous samples is prone to misinterpretation (particularly in distinguishing unaffected heterozygotes); molecular genetic testing is the preferred method in confirming prenatal diagnosis [Sperelakis-Beedham et al 2021].

### Pregnancy with low a priori risk (pregnancy not known to be at risk)

- **Fetal ultrasonography.** Although perinatal hypophosphatasia may be distinguished from other skeletal dysplasias by prenatal ultrasonography, care must be taken in the interpretation of bowed long bones. Undermineralization, small thoracic cavity, shortened long bones, and bowing are typical features of autosomal recessive and severe hypophosphatasia. However, prognosis is difficult to predict based on ultrasound findings alone: bowed and shortened long bones have been observed on prenatal ultrasound in individuals who ultimately were shown to have – variably – perinatal (benign), childhood (juvenile), or adult hypophosphatasia. The bowing resolves postnatally. In 50% of individuals, when *ALPL* molecular testing has been performed, a single pathogenic variant in *ALPL* has been identified, confirming the benign nature of the phenotype and excluding perinatal (severe) hypophosphatasia.

Differences in perspective may exist among medical professionals and within families regarding the use of prenatal testing. While most centers would consider use of prenatal testing to be a personal decision, discussion of these issues may be helpful.



## Resources

*GeneReviews staff has selected the following disease-specific and/or umbrella support organizations and/or registries for the benefit of individuals with this disorder and their families. GeneReviews is not responsible for the information provided by other organizations. For information on selection criteria, click [here](#).*

- **Hypophosphatasie Europe**  
France  
**Email:** [contact@hypophosphatasie.com](mailto:contact@hypophosphatasie.com)  
[wp.hypophosphatasie.com/accueil](http://wp.hypophosphatasie.com/accueil)
- **MAGIC Foundation**  
6645 West North Avenue  
Oak Park IL 60302  
**Phone:** 800-362-4423; 708-383-0808  
**Fax:** 708-383-0899  
**Email:** [ContactUs@magicfoundation.org](mailto:ContactUs@magicfoundation.org)  
[Hypophosphatasia](http://Hypophosphatasia)
- **Soft Bones Canada**  
PO Box 882  
Winkler Manitoba R6W 4A9  
Canada  
**Phone:** 204-202-3211  
**Email:** [contactus@softbonescanada.ca](mailto:contactus@softbonescanada.ca)  
[www.softbonescanada.ca](http://www.softbonescanada.ca)
- **Soft Bones, Inc.**  
121 Hawkins Place #267  
Boonton NJ 07005  
**Phone:** 866-827-9937  
[www.softbones.org](http://www.softbones.org)
- **National Organization for Rare Disorders (NORD)**  
**Phone:** 800-999-6673  
[RareCare® Patient Assistance Programs](#)
- **UCLA International Skeletal Dysplasia Registry (ISDR)**  
**Phone:** 310-825-8998  
[International Skeletal Dysplasia Registry](#)

## Molecular Genetics

*Information in the Molecular Genetics and OMIM tables may differ from that elsewhere in the GeneReview: tables may contain more recent information. —ED.*

**Table A.** Hypophosphatasia: Genes and Databases

Gene	Chromosome Locus	Protein	Locus-Specific Databases	HGMD	ClinVar
<i>ALPL</i>	1p36.12	Alkaline phosphatase, tissue-nonspecific isozyme	ALPL database Tissue Nonspecific Alkaline Phosphatase Gene Mutation Database	ALPL	ALPL

Data are compiled from the following standard references: gene from [HGNC](#); chromosome locus from [OMIM](#); protein from [UniProt](#). For a description of databases (Locus Specific, HGMD, ClinVar) to which links are provided, click [here](#).

**Table B.** OMIM Entries for Hypophosphatasia ([View All in OMIM](#))

146300	HYPOPHOSPHATASIA, ADULT; HPPA
171760	ALKALINE PHOSPHATASE, LIVER; ALPL
241500	HYPOPHOSPHATASIA, INFANTILE; HPPI
241510	HYPOPHOSPHATASIA, CHILDHOOD; HPPC

## Molecular Pathogenesis

*ALPL* encodes alkaline phosphatase, tissue-nonspecific isozyme (TNSALP), the isozyme present in liver, kidney, and bone. It is functional as a homodimer. The enzyme acts as a (lipid) membrane-bound ectophosphatase with inorganic pyrophosphate (PPi), pyridoxal 5'-phosphate (PLP), and phosphoethanolamine (PEA) as natural substrates.

*ALPL* pathogenic variants are distributed throughout the 12 exons of the gene. Pathogenic missense variants account for 74.6% of variants; the remainder comprise microdeletions/insertions (13.3%), pathogenic splice site variants (6.0%), pathogenic nonsense variants (3.7%), gross deletions (1.3%), and a nucleotide substitution affecting the major transcription initiation site. This variety of pathogenic variants results in highly variable clinical expression and in a great number of compound heterozygous genotypes.

Genotype-phenotype correlations have been studied using site-directed mutagenesis and 3D enzyme modeling. These studies have allowed the characterization of severe and moderate alleles (alleles producing significant residual enzymatic activity) and alleles with a dominant-negative effect responsible for dominant inheritance [Fukushi et al 1998, Shibata et al 1998, Zurutuza et al 1999, Mornet et al 2001, Watanabe et al 2002, Nasu et al 2006, Brun-Heath et al 2007, Fauvert et al 2009, Mornet et al 2021]. However, such tools do not always predict the severity of pathogenic variants.

**Mechanism of disease causation.** Pathogenic variants may result in various consequences, sometimes cumulative: decrease or abolition of the catalytic activity, inability to form homodimers, and sequestration of mutated proteins in cell compartments resulting in an inability to reach the cell membrane [Cai et al 1998, Fukushi et al 1998, Shibata et al 1998, Watanabe et al 2002, Brun-Heath et al 2007, Sultana et al 2013, Numa-Kinjoh et al 2015].

**Table 12.** Notable *ALPL* Pathogenic Variants

Reference Sequences	DNA Nucleotide Change	Predicted Protein Change	Comment [Reference]
NM_000478.6 NP_000469.3	c.1001G>A	p.Gly334Asp	Founder variant in <a href="#">Hutterite</a> Dariusleut deme [Triggs-Raine et al 2016] & Mennonites in Manitoba, Canada [Greenberg et al 1993]
	c.1559delT	p.Leu520ArgfsTer86	Founder variant in Japan [Michigami et al 2020]

Variants listed in the table have been provided by the author. *GeneReviews* staff have not independently verified the classification of variants.

*GeneReviews* follows the standard naming conventions of the Human Genome Variation Society ([varnomen.hgvs.org](http://varnomen.hgvs.org)). See [Quick Reference](#) for an explanation of nomenclature.

## Chapter Notes

### Acknowledgments

Michael Whyte, MD is the foremost authority on hypophosphatasia in all its clinical forms, and his mentorship inspires this chapter. Etienne Mornet, PhD is the foremost authority on *ALPL* variants; he co-authored the first edition of this chapter in 2007, and his continued work in the field informs this current edition. Jose Luis Millan, PhD literally wrote the book on alkaline phosphatase, and his groundbreaking basic science has transformed hypophosphatasia from a manageable to a treatable disorder.

### Author History

Etienne Mornet, PhD; Centre Hospitalier de Versailles (2007-2022)

Mark E Nunes, MD (2007-present)

### Revision History

- 30 March 2023 (ma) Revision: asfotase alfa (Strensiq<sup>®</sup>) enzyme replacement therapy added as a targeted therapy
- 7 April 2022 (sw) Comprehensive update posted live
- 4 February 2016 (ha) Comprehensive update posted live
- 10 November 2011 (cd) Revision: deletion/duplication analysis of *ALPL* available clinically
- 5 August 2010 (me) Comprehensive update posted live
- 20 November 2007 (me) Review posted live
- 18 December 2006 (men) Original submission

## References

### Literature Cited

- Brun-Heath I, Lia-Baldini AS, Maillard S, Taillandier A, Utsch B, Nunes ME, Serre JL, Mornet E. Delayed transport of tissue-nonspecific alkaline phosphatase with missense mutations causing hypophosphatasia. *Eur J Med Genet.* 2007;50:367–78. PubMed PMID: 17719863.
- Cahill RA, Wenkert D, Perlman SA, Steele A, Coburn SP, McAlister WH, Mumm S, Whyte MP. Infantile hypophosphatasia: transplantation therapy trial using bone fragments and cultured osteoblasts. *J Clin Endocrinol Metab.* 2007;92:2923–30. PubMed PMID: 17519318.
- Cai G, Michigami T, Yamamoto T, Yasui N, Satomura K, Yamagata M, Shima M, Nakajima S, Mushiaki S, Okada S, Ozono K. Analysis of localization of mutated tissue-nonspecific alkaline phosphatase proteins

- associated with neonatal hypophosphatasia using green fluorescent protein chimeras. *J Clin Endocrinol Metab.* 1998;83:3936–42. PubMed PMID: 9814472.
- Camacho PM, Mazhari AM, Wilczynski C, Kadanoff R, Mumm S, Whyte MP. Adult hypophosphatasia treated with teriparatide: report of 2 patients and review of the literature. *Endocr Pract.* 2016;22:941–50. PubMed PMID: 27042741.
- Deeb AA, Bruce SN, Morris AA, Cheetham TD. Infantile hypophosphatasia: disappointing results of treatment. *Acta Paediatr.* 2000;89:730–3. PubMed PMID: 10914973.
- Duffus S, Thrasher B, Calikoglu AS. Brief clinical report: hypophosphatasia-diagnostic considerations and treatment outcomes in an infant. *Case Rep Pediatr.* 2018;2018:5719761. PubMed PMID: 29808151.
- Fauvert D, Brun-Heath I, Lia-Baldini AS, Bellazi L, Taillandier A, Serre JL, de Mazancourt P, Mornet E. Mild forms of hypophosphatasia mostly result from dominant negative effect of severe alleles or from compound heterozygosity for severe and moderate alleles. *BMC Med Genet.* 2009;10:51. PubMed PMID: 19500388.
- Fraser D. Hypophosphatasia. *Am J Med.* 1957;22:730–46. PubMed PMID: 13410963.
- Fukushi M, Amizuka N, Hoshi K, Ozawa H, Kumagai H, Omura S, Misumi Y, Ikehara Y, Oda K. Intracellular retention and degradation of tissue-nonspecific alkaline phosphatase with a Gly317-->Asp substitution associated with lethal hypophosphatasia. *Biochem Biophys Res Commun.* 1998;246:613–8. PubMed PMID: 9618260.
- Greenberg CR, Taylor CL, Haworth JC, Seargeant LE, Philipps S, Triggs-Raine B, Chodirker BN. A homoallelic Gly317-->Asp mutation in ALPL causes the perinatal (lethal) form of hypophosphatasia in Canadian mennonites. *Genomics.* 1993;17:215–7. PubMed PMID: 8406453.
- Hacıhamdioğlu B, Özgürhan G, Pereira C, Tepeli E, Acar G, Cömert S. A case of the perinatal form hypophosphatasia caused by a novel large duplication of the ALPL gene and report of one year follow-up with enzyme replacement therapy. *J Clin Res Pediatr Endocrinol.* 2019;11:306–10. PubMed PMID: 30468149.
- Hancarova M, Krepelova A, Puchmajerova A, Soucek O, Prchalova D, Sumnik Z, Sedlacek Z. Hypophosphatasia due to uniparental disomy. *Bone.* 2015;81:765–6. PubMed PMID: 25937451.
- Huang SJ, Amendola LM, Sternen DL. Variation among DNA banking consent forms: points for clinicians to bank on. *J Community Genet.* 2022;13:389–97. PubMed PMID: 35834113.
- Huggins E, Ong R, Rockman-Greenberg C, Flueckinger LB, Dahir KM, Kishnani PS. Multigenerational case examples of hypophosphatasia: Challenges in genetic counseling and disease management. *Mol Genet Metab Rep.* 2020;25:100661. PubMed PMID: 33101980.
- Lia-Baldini AS, Muller F, Taillandier A, Gibrat JF, Mouchard M, Robin B, Simon-Bouy B, Serre JL, Aylsworth AS, Bieth E, Delanote S, Freisinger P, Hu JC, Krohn HP, Nunes ME, Mornet E. A molecular approach to dominance in hypophosphatasia. *Hum Genet.* 2001;109:99–108. PubMed PMID: 11479741.
- Michigami T, Tachikawa K, Yamazaki M, Kawai M, Kubota T, Ozono K. Hypophosphatasia in Japan: ALPL mutation analysis in 98 unrelated patients. *Calcif Tissue Int.* 2020;106:221–31. PubMed PMID: 31707452.
- Mornet E, Taillandier A, Domingues C, Dufour A, Benaloun E, Lavaud N, Wallon F, Rousseau N, Charle C, Guberto M, Muti C, Simon-Bouy B. Hypophosphatasia: a genetic-based nosology and new insights in genotype-phenotype correlation. *Eur J Hum Genet.* 2021;29:289–99. PubMed PMID: 32973344.
- Mornet E, Stura E, Lia-Baldini AS, Stigbrand T, Menez A, Le Du MH. Structural evidence for a functional role of human tissue nonspecific alkaline phosphatase in bone mineralization. *J Biol Chem.* 2001;276:31171–8. PubMed PMID: 11395499.
- Mornet E, Yvard A, Taillandier A, Fauvert D, Simon-Bouy B. A molecular-based estimation of the prevalence of hypophosphatasia in the European population. *Ann Hum Genet.* 2011;75:439–45. PubMed PMID: 21488855.

- Nasu M, Ito M, Ishida Y, Numa N, Komaru K, Nomura S, Oda K. Aberrant interchain disulfide bridge of tissue-nonspecific alkaline phosphatase with an Arg433-->Cys substitution associated with severe hypophosphatasia. *FEBS J.* 2006;273:5612–24. PubMed PMID: 17212778.
- Numa-Kinjoh N, Komaru K, Ishida Y, Sohda M, Oda K. Molecular phenotype of tissue-nonspecific alkaline phosphatase with a proline (108) to leucine substitution associated with dominant odontohypophosphatasia. *Mol Genet Metab.* 2015;115:180–5. PubMed PMID: 25982064.
- Rahbari R, Wuster A, Lindsay SJ, Hardwick RJ, Alexandrov LB, Turki SA, Dominiczak A, Morris A, Porteous D, Smith B, Stratton MR, Hurles ME, et al. Timing, rates and spectra of human germline mutation. *Nat Genet.* 2016;48:126–33. PubMed PMID: 26656846.
- Schalin-Jääntti C, Mornet E, Lamminen A, Välimäki MJ. Parathyroid hormone treatment improves pain and fracture healing in adult hypophosphatasia. *J Clin Endocrinol Metab.* 2010;95:5174–9. PubMed PMID: 20739387.
- Seefried L, Baumann J, Hemsley S, Hofmann C, Kunstmann E, Kiese B, Huang Y, Chivers S, Valentin MA, Borah B, Roubenoff R, Junker U, Jakob F. Efficacy of anti-sclerostin monoclonal antibody BPS804 in adult patients with hypophosphatasia. *J Clin Invest.* 2017;127:2148–58. PubMed PMID: 28436937.
- Shibata H, Fukushi M, Igarashi A, Misumi Y, Ikehara Y, Ohashi Y, Oda K. Defective intracellular transport of tissue-nonspecific alkaline phosphatase with an Ala162-->Thr mutation associated with lethal hypophosphatasia. *J Biochem (Tokyo).* 1998;123:968–77. PubMed PMID: 9562633.
- Spentchian M, Brun-Heath I, Taillandier A, Fauvert D, Serre JL, Simon-Bouy B, Carvalho F, Grochova I, Mehta SG, Müller G, Oberstein SL, Ogur G, Sharif S, Mornet E. Characterization of missense mutations and large deletions in the ALPL gene by sequencing and quantitative multiplex PCR of short fragments. *Genet Test.* 2006;10:252–7. PubMed PMID: 17253930.
- Sperelakis-Beedham B, Taillandier A, Domingues C, Guberto M, Colin E, Porquet-Bordes V, Rothenbuhler A, Salles JP, Wenkert D, Zankl A, Muti C, Bacrot S, Simon-Bouy B, Mornet E. Utility of genetic testing for prenatal presentations of hypophosphatasia. *Mol Genet Metab.* 2021;132:198–203. PubMed PMID: 33549410.
- Sultana S, Al-Shawafi HA, Makita S, Sohda M, Amizuka N, Takagi R, Oda K. An asparagine at position 417 of tissue-nonspecific alkaline phosphatase is essential for its structure and function as revealed by analysis of the N417S mutation associated with severe hypophosphatasia. *Mol Genet Metab.* 2013;109:282–8. PubMed PMID: 23688511.
- Tadokoro M, Kanai R, Taketani T, Uchio Y, Yamaguchi S, Ohgushi H. New bone formation by allogeneic mesenchymal stem cell transplantation in a patient with perinatal hypophosphatasia. *J Pediatr.* 2009;154:924–30. PubMed PMID: 19446101.
- Taillandier A, Sallinen SL, Brun-Heath I, De Mazancourt P, Serre JL, Mornet E. Childhood hypophosphatasia due to a de novo missense mutation in the tissue-nonspecific alkaline phosphatase gene. *J Clin Endocrinol Metab.* 2005;90:2436–9. PubMed PMID: 15671102.
- Taketani T, Kanai R, Abe M, Mishima S, Tadokoro M, Katsube Y, Yuba S, Ogushi H, Fukuda S, Yamaguchi S. Therapy-related Ph+ leukemia after both bone marrow and mesenchymal stem cell transplantation for hypophosphatasia. *Pediatr Int.* 2013;55:e52–5. PubMed PMID: 23782379.
- Taketani T, Oyama C, Mihara A, Tanabe Y, Abe M, Hirade T, Yamamoto S, Bo R, Kanai R, Tadenuma T, Michibata Y, Yamamoto S, Hattori M, Katsube Y, Ohnishi H, Sasao M, Oda Y, Hattori K, Yuba S, Ohgushi H, Yamaguchi S. Ex vivo expanded allogeneic mesenchymal stem cells with bone marrow transplantation improved osteogenesis in infants with severe hypophosphatasia. *Cell Transplant.* 2015;24:1931–43. PubMed PMID: 25396326.

- Triggs-Raine B, Dyck T, Boycott KM, Innes AM, Ober C, Parboosingh JS, Botkin A, Greenberg CR, Spriggs EL. Development of a diagnostic DNA chip to screen for 30 autosomal recessive disorders in the Hutterite population. *Mol Genet Genomic Med*. 2016;4:312–21. PubMed PMID: 27247959.
- Watanabe H, Goseki-Sone M, Orimo H, Hamatani R, Takinami H, Ishikawa I. Function of mutant (G1144A) tissue-nonspecific ALP gene from hypophosphatasia. *J Bone Miner Res*. 2002;17:1945–8. PubMed PMID: 12412800.
- Watanabe A, Karasugi T, Sawai H, Naing BT, Ikegawa S, Orimo H, Shimada T. Prevalence of c.1559delT in ALPL, a common mutation resulting in the perinatal (lethal) form of hypophosphatasia in Japanese and effects of the mutation on heterozygous carriers. *J Hum Genet*. 2011;56:166–8. PubMed PMID: 21179104.
- Watanabe A, Satoh S, Fujita A, Naing BT, Orimo H, Shimada T. Perinatal hypophosphatasia caused by uniparental isodisomy. *Bone*. 2014;60:93–7. PubMed PMID: 24334170.
- Wei KW, Xuan K, Liu YL, Fang J, Ji K, Wang X, Jin Y, Watanabe S, Watanabe K, Ojihara T. Clinical, pathological and genetic evaluations of Chinese patients with autosomal-dominant hypophosphatasia. *Arch Oral Biol*. 2010;55:1017–23. PubMed PMID: 20828673.
- Wenkert D, McAlister WH, Coburn SP, Zerega JA, Ryan LM, Ericson KL, Hersh JH, Mumm S, Whyte MP. Hypophosphatasia: nonlethal disease despite skeletal presentation in utero (17 new cases and literature review). *J Bone Miner Res*. 2011;26:2389–98. PubMed PMID: 21713987.
- Whyte MP. Atypical femoral fractures, bisphosphonates, and adult hypophosphatasia. *J Bone Miner Res*. 2009;24:1132–4. PubMed PMID: 19113923.
- Whyte MP, Kurtzberg J, McAlister WH, Mumm S, Podgornik MN, Coburn SP, Ryan LM, Miller CR, Gottesman GS, Smith AK, Douville J, Waters-Pick B, Armstrong RD, Martin PL. Marrow cell transplantation for infantile hypophosphatasia. *J Bone Miner Res*. 2003;18:624–36. PubMed PMID: 12674323.
- Whyte MP, Rockman-Greenberg C, Ozono K, Riese R, Moseley S, Melian A, Thompson DD, Bishop N, Hofmann C. Asfotase alfa treatment improves survival for perinatal and infantile hypophosphatasia. *J Clin Endocrinol Metab*. 2016;101:334–42. PubMed PMID: 26529632.
- Whyte MP, Simmons JH, Moseley S, Fujita KP, Bishop N, Salman NJ, Taylor J, Phillips D, McGinn M, McAlister WH. Asfotase alfa for infants and young children with hypophosphatasia: 7 year outcomes of a single-arm, open-label, phase 2 extension trial. *Lancet Diabetes Endocrinol*. 2019;7:93–105. PubMed PMID: 30558909.
- Yang H, Wang L, Geng J, Yu T, Yao RE, Shen Y, Yin L, Ying D, Huang R, Zhou Y, Chen H, Liu L, Mo X, Shen Y, Fu Q, Yu Y. Characterization of six missense mutations in the tissue-nonspecific alkaline phosphatase (TNSALP) gene in Chinese children with hypophosphatasia. *Cell Physiol Biochem*. 2013;32:635–44. PubMed PMID: 24022022.
- Zhang H, Ke YH, Wang C, Yue H, Hu WW, Gu JM, Zhang ZL. Identification of the mutations in the tissue-nonspecific alkaline phosphatase gene in two Chinese families with hypophosphatasia. *Arch Med Res*. 2012;43:21–30. PubMed PMID: 22300680.
- Zurutuza L, Muller F, Gibrat JF, Taillandier A, Simon-Bouy B, Serre JL, Mornet E. Correlations of genotype and phenotype in hypophosphatasia. *Hum Mol Genet*. 1999;8:1039–46. PubMed PMID: 10332035.

## License

GeneReviews® chapters are owned by the University of Washington. Permission is hereby granted to reproduce, distribute, and translate copies of content materials for noncommercial research purposes only, provided that (i) credit for source (<http://www.genereviews.org/>) and copyright (© 1993-2024 University of Washington) are included with each copy; (ii) a link to the original material is provided whenever the material is published elsewhere on the Web; and (iii) reproducers, distributors, and/or translators comply with the [GeneReviews® Copyright Notice and Usage Disclaimer](#). No further modifications are allowed. For clarity, excerpts of GeneReviews chapters for use in lab reports and clinic notes are a permitted use.

For more information, see the [GeneReviews® Copyright Notice and Usage Disclaimer](#).

For questions regarding permissions or whether a specified use is allowed, contact: [admasst@uw.edu](mailto:admasst@uw.edu).