



U.S. National Library of Medicine
National Center for Biotechnology Information

NLM Citation: Saito K. Fukuyama Congenital Muscular Dystrophy. 2006 Jan 26 [Updated 2019 Jul 3]. In: Adam MP, Feldman J, Mirzaa GM, et al., editors. GeneReviews® [Internet]. Seattle (WA): University of Washington, Seattle; 1993-2024.

Bookshelf URL: <https://www.ncbi.nlm.nih.gov/books/>



Fukuyama Congenital Muscular Dystrophy

Synonym: FCMD

Kayoko Saito, MD, PhD¹

Created: January 26, 2006; Updated: July 3, 2019.

Summary

Clinical characteristics

Fukuyama congenital muscular dystrophy (FCMD) is characterized by hypotonia, symmetric generalized muscle weakness, and CNS migration disturbances that result in changes consistent with cobblestone lissencephaly with cerebral and cerebellar cortical dysplasia. Mild, typical, and severe phenotypes are recognized. Onset typically occurs in early infancy with poor suck, weak cry, and floppiness. Affected individuals have contractures of the hips, knees, and interphalangeal joints. Later features include myopathic facial appearance, pseudohypertrophy of the calves and forearms, motor and speech delays, intellectual disability, seizures, ophthalmologic abnormalities including visual impairment and retinal dysplasia, and progressive cardiac involvement after age ten years. Swallowing disturbance occurs in individuals with severe FCMD and in individuals older than age ten years, leading to recurrent aspiration pneumonia and death.

Diagnosis/testing

The diagnosis of FCMD is established in a proband by identification of biallelic pathogenic variants in *FKTN* on molecular genetic testing.

Management

Treatment of manifestations: Physical therapy and stretching exercises, treatment of orthopedic complications, assistance devices such as long leg braces and wheelchairs, use of noninvasive respiratory aids or tracheostomy, prompt treatment of acute respiratory tract infections, anti-seizure medication, medical and/or surgical treatment for gastroesophageal reflux, gastrostomy tube placement when indicated to assure adequate caloric intake, cardiomyopathy treatment as per cardiologist.

Surveillance: Monitor:

- Respiratory function in individuals with advanced disease;

Author Affiliation: 1 Professor of Special Appointment, Institute of Medical Genetics, Tokyo Women's Medical University School of Medicine, Tokyo, Japan; Email: saito.kayoko@twmu.ac.jp.

Copyright © 1993-2024, University of Washington, Seattle. GeneReviews is a registered trademark of the University of Washington, Seattle. All rights reserved.

- For myocardial involvement by chest radiography, EKG, and echocardiography in individuals older than age ten years;
- Gastrointestinal function, and for signs/symptoms of gastroesophageal reflux;
- For foot deformities and scoliosis.

Genetic counseling

FCMD is inherited in an autosomal recessive manner. At conception, each sib of an affected individual has a 25% chance of being affected, a 50% chance of being an asymptomatic carrier, and a 25% chance of being unaffected and not a carrier. Carrier testing for at-risk family members and prenatal diagnosis for pregnancies at increased risk are possible if the pathogenic variants in the family are known.

Diagnosis

Suggestive Findings

Fukuyama congenital muscular dystrophy **should be suspected** in individuals with the following clinical, imaging, laboratory, and histopathology findings.

Clinical findings

- Early-infantile onset of hypotonia and weakness with contractures of the hips, knees, and interphalangeal joints (in 100% of individuals)
- Severe motor and speech delays and intellectual disability with relative preservation of social skills (100%)
- Static course until early childhood, followed by diffuse and extensive muscle wasting (most prominent proximally) and later progressive joint contractures (100%)
- Myopathic facial appearance (100%)
- Pseudohypertrophy of the calves and forearms in late infancy (50%)
- Seizures (febrile and/or afebrile) (50%)
- Ophthalmologic abnormalities, including visual impairment in 53% and retinal abnormalities in 32% [Saito & Kobayashi 2001]. Retinal abnormality when present is mild and focal. Retinal dysplasia, a pathologic diagnosis, is based on the finding of rosettes of immature photoreceptors.
- Family history consistent with autosomal recessive inheritance

Neuroimaging findings. MRI reveals the findings of cobblestone lissencephaly comprising five major abnormalities including the following:

- Irregular or pebbled brain surface; broad gyri with a thick cortex (pachygyria) in the frontal, parietal, and temporal regions; and sometimes areas of small and irregular gyri that resemble polymicrogyria
- Dilated lateral ventricles
- White matter abnormality with hyperintensity on T₂-weighted images and hypointensity on T₁-weighted images [Kato et al 2000] indicative of delayed myelination [Kato et al 2006, Kato et al 2010] rather than dysmyelination
- Mild brain stem hypoplasia in some individuals
- Cerebellar polymicrogyria and cerebellar cysts (23/25 individuals [Aida et al 1994])

In addition:

- The cortex is typically no more than approximately 1 cm in thickness.
- The opercula are poorly developed, leaving an open Sylvian fissure.

Laboratory findings. Serum creatine kinase (CK) concentration:

- Age <6 years: 10-60x above normal
- Age ≥7 years: 5-20x above normal
- Bedridden individuals: normal

Histopathology. Muscle biopsy:

- Findings are characteristic of muscular dystrophy. Primary feature is interstitial fibrosis without muscle degeneration and regeneration, which distinguishes Fukuyama congenital muscular dystrophy from [Duchenne muscular dystrophy](#) [Taniguchi et al 2006].
- Immunohistochemical staining using α-dystroglycan antibody reveals selective deficiency of α-dystroglycan on the surface membrane of skeletal muscle [Hayashi et al 2001].

Note: With the development of molecular genetic testing, muscle biopsy is no longer necessary to establish the diagnosis of FCMD.

EMG findings are characteristic of muscular dystrophy.

Establishing the Diagnosis

The diagnosis of Fukuyama congenital muscular dystrophy **is established** in a proband by identification of biallelic pathogenic (or likely pathogenic) variants in *FKTN* on molecular genetic testing (see Table 1 and Figure 1).

Note: (1) Per ACMG/AMP variant interpretation guidelines, the terms "pathogenic variant" and "likely pathogenic variant" are synonymous in a clinical setting, meaning that both are considered diagnostic and can be used for clinical decision making [Richards et al 2015]. Reference to "pathogenic variants" in this *GeneReview* is understood to include likely pathogenic variants. (2) Identification of biallelic *FKTN* variants of uncertain significance (or of one known *FKTN* pathogenic variant and one *FKTN* variant of uncertain significance) does not establish or rule out the diagnosis.

Molecular genetic testing approaches can include a combination of **gene-targeted testing** (single-gene testing, multigene panel) and **comprehensive genomic testing** (exome sequencing, genome sequencing) depending on the phenotype.

Gene-targeted testing requires that the clinician determine which gene(s) are likely involved, whereas genomic testing does not. Because the phenotype of FCMD is broad, individuals with the distinctive findings described in Suggestive Findings are likely to be diagnosed using gene-targeted testing (see Option 1), whereas those with a phenotype indistinguishable from many other inherited disorders with muscular dystrophy are more likely to be diagnosed using genomic testing (see Option 2).

Option 1

When the phenotypic and laboratory findings suggest the diagnosis of FCMD, molecular genetic testing approaches can include **single-gene testing** or use of a **multigene panel**:

- **Single-gene testing.** For individuals of Japanese, Korean, and/or Chinese ancestry, perform targeted analysis for the c.*4392_*4393insAB185332.1 founder variant first. If only one or no pathogenic variant is identified, perform sequence analysis of the entire gene.

Note: In persons of Korean descent, if only one or no pathogenic variant is identified, consider sequence analysis to detect the Korean founder variant c.647+2084G>T.

- **A muscular dystrophy multigene panel** that includes *FKTN* and other genes of interest (see Differential Diagnosis) is most likely to identify the genetic cause of the condition while limiting identification of

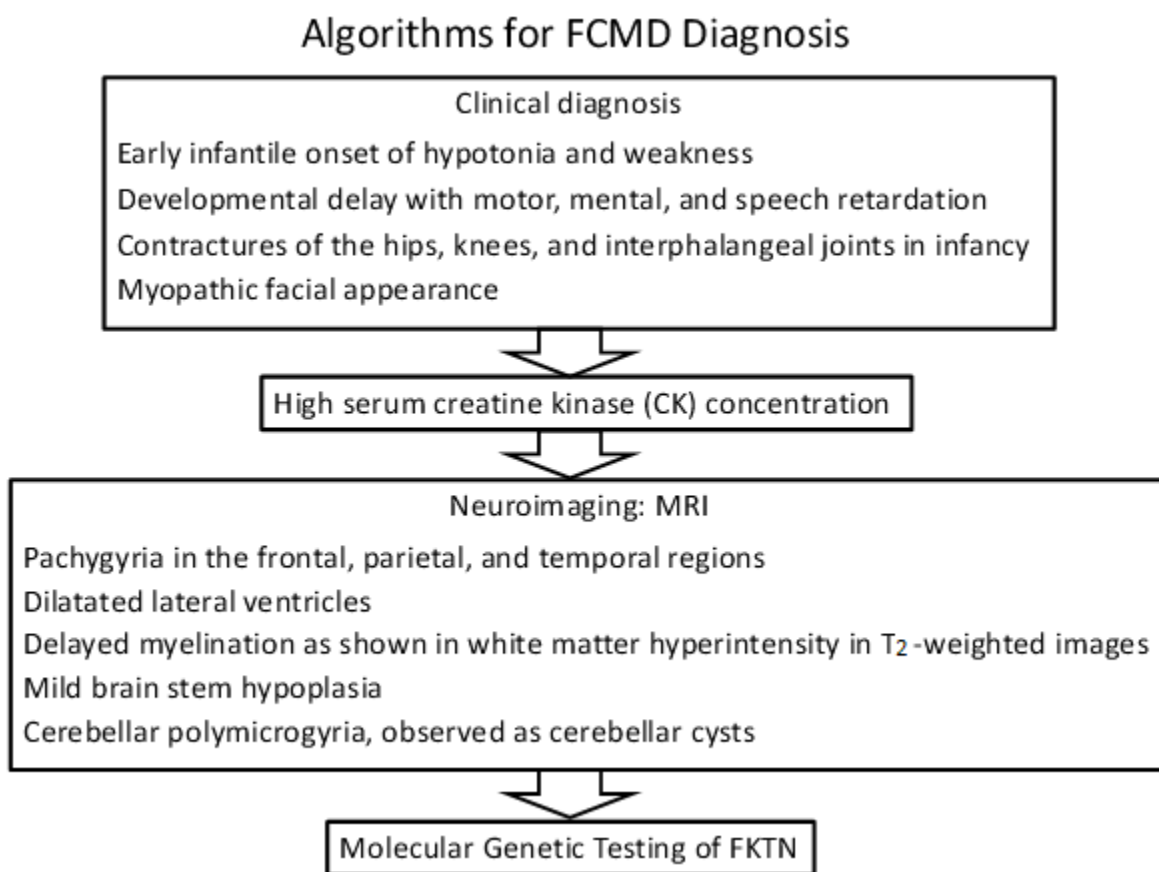


Figure 1. Diagnostic algorithm for FCMD

variants of uncertain significance and pathogenic variants in genes that do not explain the underlying phenotype. Note: (1) The genes included in the panel and the diagnostic sensitivity of the testing used for each gene vary by laboratory and are likely to change over time. (2) Some multigene panels may include genes not associated with the condition discussed in this *GeneReview*. (3) In some laboratories, panel options may include a custom laboratory-designed panel and/or custom phenotype-focused exome analysis that includes genes specified by the clinician. (4) Methods used in a panel may include sequence analysis, deletion/duplication analysis, and/or other non-sequencing-based tests.

For an introduction to multigene panels click [here](#). More detailed information for clinicians ordering genetic tests can be found [here](#).

Option 2

When the phenotype is indistinguishable from many other inherited disorders characterized by muscular dystrophy, **comprehensive genomic testing** (which does not require the clinician to determine which gene[s] are likely involved) is the best option. **Exome sequencing** is most commonly used; **genome sequencing** is also possible.

For an introduction to comprehensive genomic testing click [here](#). More detailed information for clinicians ordering genomic testing can be found [here](#).

Table 1. Molecular Genetic Testing Used in Fukuyama Congenital Muscular Dystrophy

Gene ¹	Method	Proportion of Pathogenic Variants ² Detected by Method			
		Japanese	Non-Japanese Asian	Non-Asian	
<i>FKTN</i>	Targeted analysis	c.*4392_*4393insAB185332.1	98% ³	77% ^{4, 5}	0%
		c.647+2084G>A	8%	38% (Korean)	0%
		c.139C>T	7%	60% (Chinese)	Rare
	Sequence analysis ⁶	8% ⁷	8%	100% ⁸	
	Gene-targeted deletion/duplication analysis ⁹	Rare	Rare	Rare	

1. See Table A. Genes and Databases for chromosome locus and protein.

2. See Molecular Genetics for information on variants detected in this gene.

3. In an analysis of 107 Japanese individuals with FCMD: 80 (75%) were homozygous for the founder variant; 25 (23%) were compound heterozygous for c.*4392_*4393insAB185332.1, including nine (8%) with c.647+2084G>T and seven (7%) with c.139C>T [Kobayashi et al 2017].

4. In an analysis of 13 Korean individuals with FCMD: three (23%) were homozygous for the c.*4392_*4393insAB185332.1 variant; seven (54%) were compound heterozygous for c.*4392_*4393insAB185332.1, including five (38%) with c.647+2084G>T [Lim et al 2010].

5. Yang et al [2015]

6. To detect coding and noncoding pathogenic variants, sequence analysis should include methods to detect deep intronic and splicing variants, in addition to coding and flanking intronic regions. Sequence analysis detects variants that are benign, likely benign, of uncertain significance, likely pathogenic, or pathogenic. Variants may include missense, nonsense, and splice site variants and small intragenic deletions/insertions; typically, exon or whole-gene deletions/duplications are not detected. For issues to consider in interpretation of sequence analysis results, click [here](#).

7. Sequence analysis will not identify the most common founder variant in individuals of Japanese ancestry,

c.*4392_*4393insAB185332.1.

8. Includes identification of Ashkenazi Jewish founder variant c.1167_1168insA with a carrier frequency of 0.7% (2/299 individuals) [Chang et al 2009].

9. Gene-targeted deletion/duplication analysis detects intragenic deletions or duplications. Methods used may include a range of techniques such as quantitative PCR, long-range PCR, multiplex ligation-dependent probe amplification (MLPA), and a gene-targeted microarray designed to detect single-exon deletions or duplications.

Clinical Characteristics

Clinical Description

Fukuyama congenital muscular dystrophy (FCMD) is characterized by dystrophic changes in the skeletal muscle and by CNS migration disturbances resulting in cerebral and cerebellar cortical dysplasia. The clinical features are hypotonia, weakness, and psychomotor retardation. Mild, typical, and severe phenotypes are recognized. The phenotypic spectrum ranges from a Walker-Warburg syndrome (WWS)-like phenotype at the severe end [Manzini et al 2008, Chang et al 2009, Yis et al 2011] to a limb-girdle muscular dystrophy-like phenotype at the mild end [Puckett et al 2009, Yis et al 2011, Fiorillo et al 2013].

Disease onset typically occurs in early infancy. Initial symptoms include poor suck, mildly weak cry, floppiness, and motor developmental delay. Symmetric generalized muscle weakness and hypotonia are present. Some infants exhibit poor weight gain.

Predominantly proximal hypotonia manifests as hyperextensibility of the shoulders and trunk. Limitation of hip extension, hip abduction, and knee extension is also observed and increases with time. "Puffy" cheeks and

pseudohypertrophy of the calves and forearms are evident in late infancy. Muscles are hard with a fibrous texture. Deep tendon reflexes are diminished or absent after early infancy. Facial muscle involvement (myopathic facies) is obvious from age six to 12 months and increases with age [Osawa et al 1997]. Open mouth, prognathism, and macroglossia become more evident in childhood. Swallowing difficulty develops after age six years.

Developmental delay and speech delay occur in all individuals. IQ range is usually 30 to 60. In individuals with mild FCMD, the IQ is more than 35; in individuals with severe FCMD, the IQ is less than 30. The maximum development in an individual with typical FCMD often consists of dozens of spoken words, sitting without help, and sliding along the floor on the buttocks. Individuals with mild FCMD may achieve independent walking or standing. Individuals with severe FCMD may lack head control or the ability to sit independently.

Social development of individuals with FCMD is not as severely affected as physical and mental abilities [Saito & Kobayashi 2001]. Children with FCMD tend to be the favorites in their nursery, kindergarten, or primary school. Even severely affected individuals with FCMD show eye contact, recognize family members, and make demands through vocalizations. Autistic features are not observed.

Seizures occur in more than 60% of affected individuals [Yoshioka et al 2008]. The average ages of onset of febrile and afebrile seizures were 5.4 and 4.6 years, respectively, in individuals homozygous for the Japanese founder variant (c.*4392_*4393insAB185332.1). The average ages of onset of febrile and afebrile seizures were 3.6 and 3.7 years, respectively, in individuals who were compound heterozygous for the Japanese founder variant and an additional pathogenic variant [Yoshioka et al 2008].

Ocular abnormalities include refractive error (myopia and hypermetropia) in 40%-53% of individuals. Abnormalities of the retina are seen in 32% of those with more severe FCMD [Chijiwa et al 1983, Tsutsumi et al 1989, Osawa et al 1997]; however, retinal dysplasia is mild and focal.

In a few individuals with severe FCMD confirmed with molecular genetic testing, severe ocular anomalies included microphthalmia, retinal detachment, retinal hypoplasia, cataracts, and glaucoma [Mishima et al 1985, Hino et al 2001, Saito & Kobayashi 2001, Manzini et al 2008, Chang et al 2009]. Of note, the characteristic ocular findings of muscle-eye-brain disease (MEBD) or WWS (e.g., anterior chamber abnormalities, glaucoma) are not present in FCMD.

Slowly progressive cardiac involvement is characteristic of FCMD. The clinical progression of cardiac dysfunction is significantly milder than [Duchenne muscular dystrophy](#) (DMD) [Yamamoto et al 2017]. Individuals who live more than ten years tend to develop fibrosis of the myocardium, as evidenced by postmortem findings [Finsterer et al 2010]. In an evaluation of left ventricular (LV) function using M-mode and Doppler echocardiography in 34 individuals with FCMD, eight of 11 individuals older than age 15 years showed decreased LV systolic function [Nakanishi et al 2006]. The brain natriuretic peptide concentration showed no correlation with age or left ventricular ejection fraction [Yamamoto et al 2017].

Swallowing dysfunction is observed in individuals with infantile FCMD (especially severe FCMD) and also in individuals older than age ten years with advanced disease. Inability to swallow leads to recurrent aspiration pneumonia and death [Hill et al 2004].

Murakami et al [2012] reported sudden exacerbation of muscle weakness with marked elevation of serum creatine kinase (CK) and urinary myoglobin levels a few days after a febrile episode of viral infection, occasionally leading to death.

Neuropathology. Examination of the brain in FCMD shows changes consistent with cobblestone lissencephaly with cerebral and cerebellar cortical dysplasia caused by a defect in neuronal migration [Saito et al 2000]. These changes are similar to but typically less severe than the abnormalities described in MEBD and WWS.

Infants can show extensive areas of pachygyria over the surface of the cerebral hemispheres, a feature that is more prominent over the frontal and especially temporal lobes than the parietal and occipital lobes. A variant of polymicrogyria is frequently noted over the cortical surface of the parieto-occipital lobes.

Cerebellar cysts, lined with the molecular layer and containing leptomeningeal tissue, were observed beneath the malformed cerebellar cortex or areas of polymicrogyria [Aida 1998]. Although distinctive enough to be diagnostic of cobblestone lissencephaly, these changes do not distinguish between FCMD and other causes of MEBD or WWS.

In juvenile and adult cases, the agyric areas are more focal and restricted to the occipital lobes. Lissencephalic or agyric areas of malformed cortex may alternate with regions of polymicrogyria, based on fusion of gyri and excessive migration of glio-mesenchymal tissue extending into the subarachnoid space.

A malformed or flat ventral surface of the medulla caused by secondary hypoplasia associated with a small *basis pontis* and grooves in the spinal cord has been observed [Saito & Kobayashi 2001].

In fetal cases, neurons and glia migrate through focal defects in the *glia limitans*, forming verrucous nodules, the initial manifestation of cortical dysplasia. Thus, the overmigration of CNS parenchyma into subarachnoid spaces is a pathologic process that is considered essential to the development of cortical dysplasia.

Genotype-Phenotype Correlations

Kondo-Iida et al [1999] and Kobayashi et al [2017] analyzed *FKTN* in 107 unrelated affected individuals. Individuals homozygous for the Japanese founder variant c.*4392_*4393insAB185332.1 show a milder phenotype than do compound heterozygotes who have this pathogenic variant in combination with a pathogenic missense or nonsense variant on the other allele.

The severe phenotype, including WWS-like manifestations such as hydrocephalus and microphthalmia, was significantly more common in probands who were compound heterozygous for a single-nucleotide variant and the Japanese founder variant (c.*4392_*4393insAB185332.1) [Yoshioka 2009, Kobayashi et al 2017] than in probands who were homozygous for the founder variant.

Chang et al [2009] identified a homozygous c.1167_1168insA *FKTN* pathogenic variant in four individuals with features of WWS.

Godfrey et al [2006], Godfrey et al [2007], Puckett et al [2009], Yis et al [2011], and Fiorillo et al [2013] reported a milder LGMD phenotype in individuals heterozygous for a pathogenic missense variant / frameshift variant and homozygous pathogenic missense variants (see Genetically Related Disorders).

Prevalence

FCMD is second in prevalence only to DMD among all subtypes of childhood progressive muscular dystrophy in Japan, with an incidence of 0.7-1.2 per 10,000 births. Chromosomes bearing the *FKTN* Japanese founder variant c.*4392_*4393insAB185332.1 are derived from a single ancestral founder, who lived 2,000-2,500 years ago. It was found in only one of 176 chromosomes in unrelated healthy individuals [Kobayashi et al 1998].

The average occurrence of heterozygous carriers identified in various regions of Japan is one in 188. However, in Korean populations, one carrier was detected in 935 individuals, and researchers were unable to detect any heterozygous pathogenic variants in 203 individuals of Mongolian ancestry and 766 individuals from mainland China [Watanabe et al 2005].

FCMD is pan ethnic, but most common in individuals of Japanese ancestry.

Genetically Related (Allelic) Disorders

Walker-Warburg syndrome (WWS). Pathogenic variants in *FKTN* may also be associated with WWS. WWS is one of the three major phenotypes of the dystroglycanopathies (see Differential Diagnosis).

Other phenotypes associated with germline pathogenic variants in *FKTN* are summarized in Table 2.

Table 2. Other *FKTN*-Related (Allelic) Disorders

<i>FKTN</i> -Related (Allelic) Disorder	Reference
Dilated cardiomyopathy	Dilated Cardiomyopathy Overview
Limb-girdle muscular dystrophy 1	Godfrey et al [2006], Godfrey et al [2007], Puckett et al [2009], Vuillaumier-Barrot et al [2009], Yis et al [2011]

1. Compound heterozygous *FKTN* pathogenic variants have been identified in several individuals with limb-girdle muscular dystrophy type 2M.

Differential Diagnosis

Fukuyama congenital muscular dystrophy (FCMD) is one of the congenital muscular dystrophies, a clinically and genetically heterogeneous group of inherited muscle disorders characterized by muscle weakness evident at birth or in early infancy. The main congenital muscular dystrophy (CMD) subtypes are laminin alpha-2 (merosin) deficiency (MDC1A), collagen VI-deficient CMD, the alpha-dystroglycanopathies (caused by pathogenic variants in *POMT1*, *POMT2*, *POMGNT1*, *FKTN*, *FKRP*, *LARGE1*, *CRPPA* (formerly *ISPD*), *POMGNT2*, *DAG1*, *TMEM5*, *B3GALNT2*, *POMK*, *B4GAT1*, and *GMPPB*) [Godfrey et al 2007, Godfrey et al 2011, Devisme et al 2012, Lim et al 2013, Kang et al 2015, Bouchet-Séraphin et al 2016, Taniguchi-Ikeda et al 2016] (see Table 3), *SELENON* (formerly *SEPNI*)-related CMD (previously known as rigid spine syndrome, or RSMD1), and *LMNA*-related CMD (L-CMD).

The three major phenotypes of the alpha-dystroglycanopathies are FCMD, Walker-Warburg syndrome (WWS), and muscle-eye-brain disease (MEBD) [Taniguchi et al 2003, Voglmeir et al 2011, Carss et al 2013]. The alpha-dystroglycanopathies are characterized by congenital muscular dystrophy associated with characteristic brain malformations (cobblestone [type II] lissencephaly and cerebellar malformations), eye malformations (typically involving the retina), profound intellectual disability, and early death. FCMD is milder than WWS and MEBD, particularly with respect to brain and ophthalmologic involvement [Bouchet-Séraphin et al 2016, Taniguchi-Ikeda et al 2016] (see Table 2). The alpha-dystroglycanopathies are inherited in an autosomal recessive manner.

Table 3. Distinguishing Between the Major Phenotypes of the Alpha-Dystroglycanopathies: FCMD, MEBD, and WWS

Phenotype	Gene(s)	Severity of Findings			Brain MRI			
		MD	Eye	ID	Brain stem	Cerebellum	Cerebellar cysts	Hydrocephalus
Fukuyama CMD	<i>FKTN</i>	Moderate to severe	Mild	Moderate	Usually normal; in rare cases hypoplastic	Usually normal; occasionally small	Observed	Rare
Muscle-eye-brain disease (See OMIM PS236670 .)	<i>DAG1</i> ¹ <i>GMPPB</i> ² <i>LARGE1</i> ³ <i>POMGNT1</i> ⁴ <i>POMT1</i> <i>POMT2</i>	Mild	Severe ⁵	Severe	Almost always small	Always small	Observed	Common

Table 3. continued from previous page.

Phenotype	Gene(s)	Severity of Findings			Brain MRI			
		MD	Eye	ID	Brain stem	Cerebellum	Cerebellar cysts	Hydrocephalus
Walker-Warburg syndrome (See OMIM PS236670.)	<i>B3GALNT2</i> ⁶ <i>B4GAT1</i> ⁷ <i>CRPPA (ISPD)</i> ⁸ <i>DAG1</i> ⁹ <i>FKRP</i> ¹⁰ <i>FKTN</i> <i>GMPPB</i> ² <i>LARGE1</i> ³ <i>POMGNT1</i> ⁴ <i>POMGNT2</i> ¹¹ <i>POMK</i> ¹² <i>POMT1</i> ¹³ <i>POMT2</i> ¹⁴ <i>RXYLT1 (TMEM5)</i> ¹⁵	Mild	Severe ¹⁶	Severe	Very small & kinked at junction of midbrain & pons	Very small	Observed	Almost universal

ID = intellectual disability; MD = muscle dystrophy

1. Signorino et al [2018]

2. Astrea et al [2018]

3. Meilleur et al [2014]

4. Fu et al [2017]

5. Severe congenital myopia, congenital glaucoma, pallor of the optic discs, retinal hypoplasia

6. Buysse et al [2013], Stevens et al [2013]

7. Buysse et al [2013]

8. Mutation of *CRPPA (ISPD)* causes severe WWS but is also a cause of the milder forms such as LGMD [Cirak et al 2013].

9. Riemersma et al [2015]

10. Yoshioka et al [2017]

11. Manzini et al [2012]

12. Di Costanzo et al [2014]

13. Kang et al [2015]

14. Kitamura et al [2016]

15. Praissman et al [2016]

16. Microphthalmia, retinal detachment, retinal hypoplasia, anterior chamber malformation, cataracts

Management

A consensus statement on standard of care for congenital muscular dystrophies (CMD) has been published [Wang et al 2010] ([full text](#)). Kang et al [2015] ([full text](#)) have also published an evidence-based guideline including management guidelines for individuals with CMD.

Evaluations Following Initial Diagnosis

To establish the extent of disease and needs in an individual diagnosed with Fukuyama congenital muscular dystrophy (FCMD), the following evaluations (if not performed as part of the evaluation that led to the diagnosis) are recommended:

- Neurologic evaluation, including EEG and brain MRI
- Developmental assessment including assessment of motor skills, cognition, and speech
- Physical therapy evaluation of joint range of motion
- Ophthalmologic evaluation

- Feeding and swallowing assessment in individuals who lack head control or the ability to sit without support
- Assessment of caloric intake and nutritional status
- Consultation with a clinical geneticist and/or genetic counselor

Treatment of Manifestations

There is no curative treatment for FCMD. Appropriate multidisciplinary management can prolong survival and improve the quality of life for individuals with FCMD.

Treatment includes the following:

- Physical therapy and stretching exercises to promote mobility and prevent contractures
- When scoliosis is present, spinal fusion to preserve breathing function and improve sitting balance [Takaso et al 2010, Hino et al 2017, Saito et al 2017]
- Use of mechanical assistance such as long leg braces to maintain standing posture and wheelchairs to help mobility
- Use of respiratory aids such as nasal intermittent positive pressure ventilator when indicated [Sato et al 2016]

Note: Noninvasive ventilation is offered, particularly at night, before respiratory distress becomes acute.

- Prompt treatment of acute respiratory tract infections; particularly important, as these infections are the most common cause of hospital admissions and death in people with FCMD
- Anti-seizure medication when indicated
- Medical and/or surgical treatment for gastroesophageal reflux when indicated
- Gastrostomy tube placement when indicated to assure adequate caloric intake
- Cardiomyopathy treatment as per cardiologist

Surveillance

The following surveillance based on evidence-based guidelines [Kang et al 2015] is intended to promote growth and potential development, mitigate comorbidities, optimize function, and limit mortality while maximizing quality of life:

- Clinical evaluation of individuals with seizures at least every three months and EEG every six months
- Monitoring of respiratory function in individuals with advanced FCMD who are older than age ten years. Those who survive beyond age 20 years may require tracheostomy or noninvasive respiratory support.
- Monitoring of myocardial involvement by chest radiography, EKG, and echocardiography in individuals older than age ten years
- Observation/evaluation of gastrointestinal function by a qualified specialist, using a video-fluoroscopic swallow assessment, upper-gastrointestinal tract image, and pH monitor for gastroesophageal reflux
- Monitoring for foot deformities and scoliosis

Evaluation of Relatives at Risk

See Genetic Counseling for issues related to testing of at-risk relatives for genetic counseling purposes.

Therapies Under Investigation

Antisense oligonucleotide therapy. Taniguchi-Ikeda et al [2011] reported that introduction of targeted antisense oligonucleotides in cell cultures of individuals with FCMD and in model mice rescued normal fukutin mRNA expression and protein production. Their work has demonstrated the promise of splicing modulation therapy as a radical clinical treatment for FCMD.

Supplementation therapy. Kanagawa et al [2016] reported that ribitol 5-phosphate is a functional glycan unit in mammals and that defects in its post-translational modification pathway are a cause of *CRPPA*- (formerly *ISPD*), *FKRP*-, and *FKTN*-related alpha-dystroglycanopathies. Since D-ribitol-5-phosphate cytidyltransferase (also known as isoprenoid synthase domain-containing protein, or *ISPD*) deficiency leads to a loss of or severe reduction in cellular CDP-ribitol, the supplementation of CDP-ribitol may be effective in treating FCMD. Gerin et al [2016] showed that ribitol supplementation to fibroblasts from individuals with *CRPPA* pathogenic variants leads to a partial rescue of alpha-dystroglycan glycosylation.

Gene therapy. The effectiveness of recombinant adeno-associated virus serotype 9-mediated fukutin and *FKRP* gene delivery has been demonstrated using FCMD and LGMD model mice, respectively [Kanagawa et al 2013, Xu et al 2013]. Earlier intervention would be highly preferred [Vannoy et al 2017].

Search [ClinicalTrials.gov](https://clinicaltrials.gov) in the US and [EU Clinical Trials Register](https://www.eurotrials.org/) in Europe for information on clinical studies for a wide range of diseases and conditions.

Genetic Counseling

Genetic counseling is the process of providing individuals and families with information on the nature, mode(s) of inheritance, and implications of genetic disorders to help them make informed medical and personal decisions. The following section deals with genetic risk assessment and the use of family history and genetic testing to clarify genetic status for family members; it is not meant to address all personal, cultural, or ethical issues that may arise or to substitute for consultation with a genetics professional. —ED.

Mode of Inheritance

Fukuyama congenital muscular dystrophy (FCMD) is inherited in an autosomal recessive manner.

Risk to Family Members

Parents of a proband

- The parents of an affected child are obligate heterozygotes (i.e., carriers of one *FKTN* pathogenic variant).
- Heterozygotes (carriers) are asymptomatic and are not at risk of developing the disorder.

Sibs of a proband

- At conception, each sib of an affected individual has a 25% chance of being affected, a 50% chance of being an asymptomatic carrier, and a 25% chance of being unaffected and not a carrier.
- Heterozygotes (carriers) are asymptomatic and are not at risk of developing the disorder.

Offspring of a proband. Individuals with FCMD are not known to reproduce.

Other family members. Each sib of the proband's parents is at a 50% risk of being a carrier of a *FKTN* pathogenic variant.

Carrier (Heterozygote) Detection

Carrier testing for at-risk relatives requires prior identification of the *FKTN* pathogenic variants in the family.

Related Genetic Counseling Issues

Family planning

- The optimal time for determination of genetic risk, clarification of carrier status, and discussion of the availability of prenatal testing is before pregnancy.
- It is appropriate to offer genetic counseling (including discussion of potential risks to offspring and reproductive options) to young adults who are carriers or are at risk of being carriers.

DNA banking. Because it is likely that testing methodology and our understanding of genes, pathogenic mechanisms, and diseases will improve in the future, consideration should be given to banking DNA from probands in whom a molecular diagnosis has not been confirmed (i.e., the causative pathogenic mechanism is unknown). For more information, see Huang et al [2022].

Prenatal Testing and Preimplantation Genetic Testing

Once the *FKTN* pathogenic variants have been identified in an affected family member, prenatal and preimplantation genetic testing are possible.

Resources

GeneReviews staff has selected the following disease-specific and/or umbrella support organizations and/or registries for the benefit of individuals with this disorder and their families. GeneReviews is not responsible for the information provided by other organizations. For information on selection criteria, click [here](#).

- **Cure CMD**
Phone: 562-444-5656
www.curecmd.org
- **European Neuromuscular Centre (ENMC)**
Netherlands
Phone: 31 35 5480481
Email: enmc@enmc.org
enmc.org
- **Japan Muscular Dystrophy Association**
Japan
Phone: 03-6907-3521
jmda.or.jp
- **Muscular Dystrophy Association (MDA) - USA**
Phone: 833-275-6321
Email: ResourceCenter@mdausa.org
mda.org

- **Muscular Dystrophy UK**

United Kingdom

Phone: 0800 652 6352

muscular dystrophyuk.org

- **Congenital Muscle Disease International Registry (CMDIR)**

The CMDIR is a global partnership of patient advocacy organizations, researchers, and clinicians, all working toward the same goal: to find treatments for congenital muscle disease.

CMDIR/Cure CMD

cmdir.org

Molecular Genetics

Information in the Molecular Genetics and OMIM tables may differ from that elsewhere in the GeneReview: tables may contain more recent information. —ED.

Table A. Fukuyama Congenital Muscular Dystrophy: Genes and Databases

Gene	Chromosome Locus	Protein	Locus-Specific Databases	HGMD	ClinVar
<i>FKTN</i>	9q31.2	Ribitol-5-phosphate transferase FKTN	FKTN homepage - Leiden Muscular Dystrophy pages	FKTN	FKTN

Data are compiled from the following standard references: gene from [HGNC](#); chromosome locus from [OMIM](#); protein from [UniProt](#). For a description of databases (Locus Specific, HGMD, ClinVar) to which links are provided, click [here](#).

Table B. OMIM Entries for Fukuyama Congenital Muscular Dystrophy ([View All in OMIM](#))

253800	MUSCULAR DYSTROPHY-DYSTROGLYCANOPATHY (CONGENITAL WITH BRAIN AND EYE ANOMALIES), TYPE A, 4; MDDGA4
607440	FUKUTIN; FKTN

Molecular Pathogenesis

Introduction. The dystroglycanopathy genes *FKTN*, *FKRP*, and *CRPPA* (formerly *ISPD*) encode essential enzymes for the synthesis of the structure: fukutin and ribitol 5-phosphate transferase FKRP (FKRP) transfer ribitol-phosphate onto sugar chains of alpha-dystroglycan, and D-ribitol-5-phosphate cytidyltransferase (also known as isoprenoid synthase domain-containing protein, or ISPD) synthesizes CDP-ribitol, a donor substrate for fukutin and FKRP [Kanagawa et al 2016]. Fukutin, FKRP, and ISPD are directly involved in the synthesis of the tandem RboP: fukutin and FKRP are RboP transferases, and ISPD is involved in cellular CDP-ribitol synthesis [Kanagawa et al 2016]. In addition, TMEM5 is a UDP-xylosyl transferase enzyme for modification of ribitol that is in a phosphodiester linkage to the core M3 glycan on alpha-dystroglycan [Praisman et al 2016].

Mechanism of disease causation. Loss of function. FCMD is a disease of ribitol-phosphate deficiency.

Table 4. Notable *FKTN* Pathogenic Variants

Reference Sequences	DNA Nucleotide Change	Predicted Protein Change	Comment [Reference]
NM_001079802.1 NP_001073270.1	c.1167_1168insA	p.Phe390IlefsTer14	Founder variant in Ashkenazi Jewish [Chang et al 2009]
NM_006731.2 NP_006722.2	c.647+2084G>T ¹	p.Arg216SerfsTer10	Founder variant in Korea [Lim et al 2010]; 2nd most common variant in Japan [Kobayashi et al 2017]
NM_006731.2	c.*4392_*4393insAB185332.1 ^{2,3}		Founder variant in Japan [Kobayashi et al 1998]
NM_001079802.1 NP_001073270.1	c.139C>T	p.Arg47Ter	3rd most common variant in Japan [Kobayashi et al 2017]

Variants listed in the table have been provided by the author. *GeneReviews* staff have not independently verified the classification of variants.

GeneReviews follows the standard naming conventions of the Human Genome Variation Society (varnomen.hgvs.org). See [Quick Reference](#) for an explanation of nomenclature.

1. Deep intronic variant of intron that activates a pseudoexon

2. A 3-kb retrotransposon insertion of tandemly repeated sequences in the 3' untranslated region [Kato et al 2004]. Asterisk denotes a variant in the 3' UTR; the number indicates the nucleotide position beyond the stop codon. [AB185332.1](#) is the accession number of the sequence of the inserted retrotransposon.

3. Also known as [NM_001079802.1:c.*4392_4393ins3062](#)

Chapter Notes

Revision History

- 3 July 2019 (sw) Comprehensive update posted live
- 10 May 2012 (me) Comprehensive update posted live
- 26 January 2006 (me) Review posted live
- 8 October 2004 (ks) Original submission

References

Published Guidelines / Consensus Statements

Kang PB, Morrison L, Iannaccone ST, Graham RJ, Bönnemann CG, Rutkowski A, Hornyak J, Wang CH, North K, Oskoui M, Getchius TS, Cox JA, Hagen EE, Gronseth G, Griggs RC; Guideline Development Subcommittee of the American Academy of Neurology and the Practice Issues Review Panel of the American Association of Neuromuscular & Electrodiagnostic Medicine. Evidence-based guideline summary: evaluation, diagnosis, and management of congenital muscular dystrophy. Available [online](#). 2015. Accessed 3-3-22.

Wang CH, Bönnemann CG, Rutkowski A, Sejersen T, Bellini J, Battista V, Florence JM, Schara U, Schuler PM, Wahbi K, Aloysius A, Bash RO, Bérout C, Bertini E, Bushby K, Cohn RD, Connolly AM, Deconinck N, Desguerre I, Eagle M, Estournet-Mathiaud B, Ferreira A, Fujak A, Goemans N, Iannaccone ST, Jouinot P, Main M, Melacini P, Mueller-Felber W, Muntoni F, Nelson LL, Rahbek J, Quijano-Roy S, Sewry C, Storhaug K, Simonds A, Tseng B, Vajsar J, Vianello A, Zeller R; International Standard of Care Committee

for Congenital Muscular Dystrophy. Consensus statement on standard of care for congenital muscular dystrophies. Available [online](#). 2010. Accessed 3-3-22.

Literature Cited

- Aida N. Fukuyama congenital muscular dystrophy: a neuroradiologic review. *J Magn Reson Imaging*. 1998;8:317–26. PubMed PMID: 9562058.
- Aida N, Yagishita A, Takada K, Katsumata Y. Cerebellar MR in Fukuyama congenital muscular dystrophy: polymicrogyria with cystic lesions. *AJNR Am J Neuroradiol*. 1994;15:1755–9. PubMed PMID: 7847224.
- Astrea G, Romano A, Angelini C, Antozzi CG, Barresi R, Battini R, Battisti C, Bertini E, Bruno C, Cassandrini D, Fanin M, Fattori F, Fiorillo C, Guerrini R, Maggi L, Mercuri E, Morani F, Mora M, Moro F, Pezzini I, Picillo E, Pinelli M, Politano L, Rubegni A, Sanseverino W, Savarese M, Striano P, Torella A, Trevisan CP, Trovato R, Zараieva I, Muntoni F, Nigro V, D'Amico A, Santorelli FM, et al. Broad phenotypic spectrum and genotype-phenotype correlations in GMPPB-related dystroglycanopathies: an Italian cross-sectional study. *Orphanet J Rare Dis*. 2018;13:170. PubMed PMID: 30257713.
- Bouchet-S raphin C, Chelbi-Viallon M, Vuillaumier-Barrot S, Seta N. Genes of alpha-dystroglycanopathies in 2016. Article in French. *Med Sci (Paris)*. 2016;32:40–5. PubMed PMID: 27869076.
- Buyse K, Riemersma M, Powell G, van Reeuwijk J, Chitayat D, Roscioli T, Kamsteeg EJ, van den Elzen C, van Beusekom E, Blaser S, Babul-Hirji R, Halliday W, Wright GJ, Stemple DL, Lin YY, Lefeber DJ, van Bokhoven H. Missense mutations in beta-1,3-N-acetylglucosaminyltransferase 1 (B3GNT1) cause Walker-Warburg syndrome. *Hum Mol Genet*. 2013;22:1746–54. PubMed PMID: 23359570.
- Carss KJ, Stevens E, Foley AR, Cirak S, Riemersma M, Torelli S, Hoischen A, Willer T, van Scherpenzeel M, Moore SA, Messina S, Bertini E, B nnemann CG, Abdenur JE, Grosmann CM, Kesari A, Punetha J, Quinlivan R, Waddell LB, Young HK, Wraige E, Yau S, Brodd L, Feng L, Sewry C, MacArthur DG, North KN, Hoffman E, Stemple DL, Hurler ME, van Bokhoven H, Campbell KP, Lefeber DJ, Lin YY, Muntoni F, et al. Mutations in GDP-mannose pyrophosphorylase B cause congenital and limb-girdle muscular dystrophies associated with hypoglycosylation of alpha-dystroglycan. *Am J Hum Genet*. 2013;93:29–41. PubMed PMID: 23768512.
- Chang W, Winder TL, LeDuc CA, Simpson LL, Millar WS, Dungan J, Ginsberg N, Plaga S, Moore SA, Chung WK. Founder fukutin mutation causes Walker-Warburg syndrome in four Ashkenazi Jewish families. *Prenat Diagn*. 2009;29:560–9. PubMed PMID: 19266496.
- Chijiwa T, Nishimura M, Inomata H, Yamana T, Narazaki O, Kurokawa T. Ocular manifestations of congenital muscular dystrophy (Fukuyama type). *Ann Ophthalmol*. 1983;15:921–3, 926–8. PubMed PMID: 6651132.
- Cirak S, Foley AR, Herrmann R, Willer T, Yau S, Stevens E, Torelli S, Brodd L, Kamynina A, Vondracek P, Roper H, Longman C, Korinthenberg R, Marrosu G, N rnberg P, Michele DE, Plagnol V, Hurler M, Moore SA, Sewry CA, Campbell KP, Voit T, Muntoni F, et al. ISPD gene mutations are a common cause of congenital and limb-girdle muscular dystrophies. *Brain*. 2013;136:269–81. PubMed PMID: 23288328.
- Devisme L, Bouchet C, Gonzal s M, Alanio E, Bazin A, Bessi res B, Bigi N, Blanchet P, Bonneau D, Bonni res M, Bucourt M, Carles D, Clarisse B, Delahaye S, Fallet-Bianco C, Figarella-Branger D, Gaillard D, Gasser B, Delezoide AL, Guimiot F, Joubert M, Laurent N, Laquerri re A, Liprandi A, Loget P, Marcorelles P, Martinovic J, Menez F, Patrier S, Pelluard F, Perez MJ, Rouleau C, Triau S, Atti -Bitach T, Vuillaumier-Barrot S, Seta N, Encha-Razavi F. Cobblestone lissencephaly: neuropathological subtypes and correlations with genes of dystroglycanopathies. *Brain*. 2012;135:469–82. PubMed PMID: 22323514.
- Di Costanzo S, Balasubramanian A, Pond HL, Rozkalne A, Pantaleoni C, Saredi S, Gupta VA, Sunu CM, Yu TW, Kang PB, Salih MA, Mora M, Gussoni E, Walsh CA, Manzini MC. POMK mutations disrupt muscle development leading to a spectrum of neuromuscular presentations. *Hum Mol Genet*. 2014;23:5781–92. PubMed PMID: 24925318.

- Finsterer J, Ramaciotti C, Wang CH, Wahbi K, Rosenthal D, Duboc D, Melacini P. Cardiac findings in congenital muscular dystrophies. *Pediatrics*. 2010;126:538–45. PubMed PMID: 20679303.
- Fiorillo C, Moro F, Astrea G, Morales MA, Baldacci J, Marchese M, Scapolan S, Bruno C, Battini R, Santorelli FM. Novel mutations in the fukutin gene in a boy with asymptomatic hyperCKemia. *Neuromuscul Disord*. 2013;23:1010–5. PubMed PMID: 24144914.
- Fu X, Yang H, Jiao H, Wang S, Liu A, Li X, Xiao J, Yang Y, Wu X, Xiong H. Novel copy number variation of POMGNT1 associated with muscle-eye-brain disease detected by next-generation sequencing. *Sci Rep*. 2017;7:7056. PubMed PMID: 28765568.
- Gerin I, Ury B, Breloy I, Bouchet-Seraphin C, Bolsée J, Halbout M, Graff J, Vertommen D, Muccioli GG, Seta N, Cuisset JM, Dabaj I, Quijano-Roy S, Grahn A, Van Schaftingen E, Bommer GT. ISPD produces CDP-ribitol used by FKTN and FKRP to transfer ribitol phosphate onto α -dystroglycan. *Nat Commun*. 2016;7:11534. PubMed PMID: 27194101.
- Godfrey C, Clement E, Mein R, Brockington M, Smith J, Talim B, Straub V, Robb S, Quinlivan R, Feng L, Jimenez-Mallebrera C, Mercuri E, Manzur AY, Kinali M, Torelli S, Brown SC, Sewry CA, Bushby K, Topaloglu H, North K, Abbs S, Muntoni F. Refining genotype phenotype correlations in muscular dystrophies with defective glycosylation of dystroglycan. *Brain*. 2007;130:2725–35. PubMed PMID: 17878207.
- Godfrey C, Escolar D, Brockington M, Clement EM, Mein R, Jimenez-Mallebrera C, Torelli S, Feng L, Brown SC, Sewry CA, Rutherford M, Shapira Y, Abbs S, Muntoni F. Fukutin gene mutations in steroid-responsive limb girdle muscular dystrophy. *Ann Neurol*. 2006;60:603–10. PubMed PMID: 17044012.
- Godfrey C, Foley AR, Clemen E, Muntoni F. Dystroglycanopathies: coming into focus. *Curr Opin Genet Dev*. 2011;21:278–85. PubMed PMID: 21397493.
- Hayashi YK, Ogawa M, Tagawa K, Noguchi S, Ishihara T, Nonaka I, Arahata K. Selective deficiency of alpha-dystroglycan in Fukuyama-type congenital muscular dystrophy. *Neurology*. 2001;57:115–21. PubMed PMID: 11445638.
- Hill M, Hughes T, Milford C. Treatment for swallowing difficulties (dysphagia) in chronic muscle disease. *Cochrane Database Syst Rev*. 2004;2:CD004303. PubMed PMID: 15106246.
- Hino K, Fukuda M, Morino T, Ogata T, Ito M, Ishii E. Spinal fusion in a patient with Fukuyama congenital muscular dystrophy. *Brain Dev*. 2017;39:613–6. PubMed PMID: 28318781.
- Hino N, Kobayashi M, Shibata N, Yamamoto T, Saito K, Osawa M. Clinicopathological study on eyes from cases of Fukuyama type congenital muscular dystrophy. *Brain Dev*. 2001;23:97–107. PubMed PMID: 11248458.
- Huang SJ, Amendola LM, Sternen DL. Variation among DNA banking consent forms: points for clinicians to bank on. *J Community Genet*. 2022;13:389–97. PubMed PMID: 35834113.
- Kanagawa M, Kobayashi K, Tajiri M, Manya H, Kuga A, Yamaguchi Y, Akasaka-Manya K, Furukawa JI, Mizuno M, Kawakami H, Shinohara Y, Wada Y, Endo T, Toda T. Identification of a post-translational modification with ribitol-phosphate and its defect in muscular dystrophy. *Cell Rep*. 2016;14:2209–23. PubMed PMID: 26923585.
- Kanagawa M, Yu CC, Ito C, Fukada S, Hozoji-Inada M, Chiyo T, Kuga A, Matsuo M, Sato K, Yamaguchi M, Ito T, Ohtsuka Y, Katanosaka Y, Miyagoe-Suzuki Y, Naruse K, Kobayashi K, Okada T, Takeda S, Toda T. Impaired viability of muscle precursor cells in muscular dystrophy with glycosylation defects and amelioration of its severe phenotype by limited gene expression. *Hum Mol Genet*. 2013;22:3003–15. PubMed PMID: 23562821.
- Kang PB, Morrison L, Iannaccone ST, Graham RJ, Bönnemann CG, Rutkowski A, Hornyak J, Wang CH, North K, Oskoui M, Getchius TS, Cox JA, Hagen EE, Gronseth G, Griggs RC, et al. Evidence-based guideline summary: evaluation, diagnosis, and management of congenital muscular dystrophy: Report of the

- Guideline Development Subcommittee of the American Academy of Neurology and the Practice Issues Review Panel of the American Association of Neuromuscular & Electrodiagnostic Medicine. *Neurology*. 2015;84:1369–78. PubMed PMID: 25825463.
- Kato R, Kawamura J, Sugawara H, Niikawa N, Matsumoto N. A rapid diagnostic method for a retrotransposal insertional mutation into the FCMD gene in Japanese patients with Fukuyama congenital muscular dystrophy. *Am J Med Genet A*. 2004;127A:54–7. PubMed PMID: 15103718.
- Kato T, Funahashi M, Matsui A, Takashima S, Suzuki Y. MRI of disseminated developmental dysmyelination in Fukuyama type of CMD. *Pediatr Neurol*. 2000;23:385–8. PubMed PMID: 11118792.
- Kato Z, Morimoto M, Orii KE, Kato T, Kondo N. Developmental changes of radiological findings in Fukuyama-type congenital muscular dystrophy. *Pediatr Radiol*. 2010;40:S127–9. PubMed PMID: 20571791.
- Kato Z, Saito K, Isogai K, Kondo N. Magnetic resonance imaging and spectroscopy in Fukuyama-type congenital muscular dystrophy. *J Pediatr Neurol*. 2006;4:261–4.
- Kitamura Y, Kondo E, Urano M, Aoki R, Saito K. Target resequencing of neuromuscular disease-related genes using next-generation sequencing for patients with undiagnosed early-onset neuromuscular disorders. *J Hum Genet*. 2016;61:931–42. PubMed PMID: 27357428.
- Kobayashi K, Kato R, Kondo-Iida E, Taniguchi-Ikeda M, Osawa M, Saito K, Toda T. Deep-intronic variant of fukutin is the most prevalent point mutation of Fukuyama congenital muscular dystrophy in Japan. *J Hum Genet*. 2017;62:945–8. PubMed PMID: 28680109.
- Kobayashi K, Nakahori Y, Miyake M, Matsumura K, Kondo-Iida E, Nomura Y, Segawa M, Yoshioka M, Saito K, Osawa M, Hamano K, Sakakihara Y, Nonaka I, Nakagome Y, Kanazawa I, Nakamura Y, Tokunaga K, Toda T. An ancient retrotransposal insertion causes Fukuyama-type congenital muscular dystrophy. *Nature*. 1998;394:388–92. PubMed PMID: 9690476.
- Kondo-Iida E, Kobayashi K, Watanabe M, Sasaki J, Kumagai T, Koide H, Saito K, Osawa M, Nakamura Y, Toda T. Novel mutations and genotype-phenotype relationships in 107 families with Fukuyama-type congenital muscular dystrophy (FCMD). *Hum Mol Genet*. 1999;8:2303–9. PubMed PMID: 10545611.
- Lim BC, Ki C-S, Kim J-W, Cho A, Kim MJ, Hwang H, Kim KJ, Hwang YS, Park WY, Lim Y-J, Kim IO, Lee JS, Chae JH. Fukutin mutations in congenital muscular dystrophies with defective glycosylation of dystroglycan in Korea. *Neuromuscul Disord*. 2010;20:524–30. PubMed PMID: 20620061.
- Lim BC, Lee S, Shin JY, Hwang H, Kim KJ, Hwang YS, Seo JS, Kim JI, Chae JH. Molecular diagnosis of congenital muscular dystrophies with defective glycosylation of alpha-dystroglycan using next-generation sequencing technology. *Neuromuscul Disord*. 2013;23:337–44. PubMed PMID: 23453855.
- Manzini MC, Gleason D, Chang BS, Hill RS, Barry BJ, Partlow JN, Poduri A, Currier S, Galvin-Parton P, Shapiro LR, Schmidt K, Davis JG, Basel-Vanagaite L, Seidahmed MZ, Salih MAM, Dobyns WB, Walsh CA. Ethnically diverse causes of Walker-Warburg syndrome (WWS): FCMD mutations are a more common cause of WWS outside of the Middle East. *Hum Mutat*. 2008;29:E231–41. PubMed PMID: 18752264.
- Manzini MC, Tambunan DE, Hill RS, Yu TW, Maynard TM, Heinzen EL, Shianna KV, Stevens CR, Partlow JN, Barry BJ, Rodriguez J, Gupta VA, Al-Qudah AK, Eyaid WM, Friedman JM, Salih MA, Clark R, Moroni I, Mora M, Beggs AH, Gabriel SB, Walsh CA. Exome sequencing and functional validation in zebrafish identify GTDC2 mutations as a cause of Walker-Warburg syndrome. *Am J Hum Genet*. 2012;91:541–7. PubMed PMID: 22958903.
- Meilleur KG, Zukosky K, Medne L, Fequiere P, Powell-Hamilton N, Winder TL, Alsaman A, El-Hattab AW, Dastgir J, Hu Y, Donkervoort S, Golden JA, Eagle R, Finkel R, Scavina M, Hood IC, Rorke-Adams LB, Bönnemann CG. Clinical, pathologic, and mutational spectrum of dystroglycanopathy caused by LARGE mutations. *J Neuropathol Exp Neurol*. 2014;73:425–41. PubMed PMID: 24709677.

- Mishima H, Hirata H, Ono H, Choshi K, Nishi Y, Fukuda K. A Fukuyama type of congenital muscular dystrophy associated with atypical gyrate atrophy of the choroid and retina. A case report. *Acta Ophthalmol (Copenh)*. 1985;63:155–9. PubMed PMID: 4003043.
- Murakami T, Ishigaki K, Shirakawa S, Ikenaka H, Sakauchi M, Osawa M. Severe muscle damage following viral infection in patients with Fukuyama congenital muscular dystrophy. *Brain Dev*. 2012;34:293–7. PubMed PMID: 21726969.
- Nakanishi T, Sakauchi M, Kaneda Y, Tomimatsu H, Saito K, Nakazawa M, Osawa M. Cardiac involvement in Fukuyama-type congenital muscular dystrophy. *Pediatrics*. 2006;117:e1187–92. PubMed PMID: 16717122.
- Osawa M, Sumida S, Suzuki N, Arai Y, Ikenaka H, Murasugi H, Shishikura K, Suzuki H, Saito K, Fukuyama Y. Fukuyama type congenital muscular dystrophy. In: Fukuyama Y, Osawa M, Saito K, eds. *Congenital Muscular Dystrophies*. Amsterdam, Netherlands: Elsevier Science; 1997:31–68.
- Praissman JL, Willer T, Sheikh MO, Toi A, Chitayat D, Lin YY, Lee H, Stalnaker SH, Wang S, Prabhakar PK, Nelson SF, Stemple DL, Moore SA, Moremen KW, Campbell KP, Wells L. The functional O-mannose glycan on alpha-dystroglycan contains a phospho-ribitol primed for matriglycan addition. *Elife*. 2016;5. PubMed PMID: 27130732.
- Puckett RL, Moore SA, Winder TL, Willer T, Romansky SG, Covault KK, Campbell KP, Abdenur JE. Further evidence of Fukutin mutations as a cause of childhood onset limb-girdle muscular dystrophy without mental retardation. *Neuromuscul Disord*. 2009;19:352–6. PubMed PMID: 19342235.
- Richards S, Aziz N, Bale S, Bick D, Das S, Gastier-Foster J, Grody WW, Hegde M, Lyon E, Spector E, Voelkerding K, Rehm HL, et al. Standards and guidelines for the interpretation of sequence variants: a joint consensus recommendation of the American College of Medical Genetics and Genomics and the Association for Molecular Pathology. *Genet Med*. 2015;17:405–24. PubMed PMID: 25741868.
- Riemersma M, Mandel H, van Beusekom E, Gazzoli I, Roscioli T, Eran A, Gershoni-Baruch R, Gershoni M, Pietrokovski S, Vissers LE, Lefeber DJ, Willemsen MA, Wevers RA, van Bokhoven H. Absence of α - and β -dystroglycan is associated with Walker-Warburg syndrome. *Neurology*. 2015;84:2177–82. PubMed PMID: 25934851.
- Saito K, Kobayashi M. Fukuyama congenital muscular dystrophy. In: Emery AEH, ed. *Muscular Dystrophies*. Oxford, UK: Oxford University Press; 2001:39–54.
- Saito W, Namba T, Inoue G, Imura T, Miyagi M, Nakazawa T, Shirasawa E, Uchida K, Takaso M. Spinal correction in patients with Fukuyama congenital muscular dystrophy. *J Orthop Sci*. 2017;22:658–64. PubMed PMID: 28325699.
- Saito Y, Mizuguchi M, Oka A, Takashima S. Fukutin protein is expressed in neurons of the normal developing human brain but is reduced in Fukuyama-type congenital muscular dystrophy brain. *Ann Neurol*. 2000;47:756–64. PubMed PMID: 10852541.
- Sato T, Murakami T, Ishiguro K, Shichiji M, Saito K, Osawa M, Nagata S, Ishigaki K. Respiratory management of patients with Fukuyama congenital muscular dystrophy. *Brain Dev*. 2016;38:324–30. PubMed PMID: 26363734.
- Signorino G, Covaceuszach S, Bozzi M, Hübner W, Mönkemöller V, Konarev PV, Cassetta A, Brancaccio A, Sciandra F. A dystroglycan mutation (p.Cys667Phe) associated to muscle-eye-brain disease with multicystic leucodystrophy results in ER-retention of the mutant protein. *Hum Mutat*. 2018;39:266–80. PubMed PMID: 29134705.
- Stevens E, Carss KJ, Cirak S, Foley AR, Torelli S, Willer T, Tambunan DE, Yau S, Brodd L, Sewry CA, Feng L, Haliloglu G, Orhan D, Dobyns WB, Enns GM, Manning M, Krause A, Salih MA, Walsh CA, Hurles M, Campbell KP, Manzini MC, Stemple D, Lin YY, Muntoni F, et al. Mutations in B3GALNT2 cause congenital muscular dystrophy and hypoglycosylation of alpha-dystroglycan. *Am J Hum Genet*. 2013;92:354–65. PubMed PMID: 23453667.

- Takaso M, Nakazawa T, Imura T, Okada T, Ueno M, Saito W, Takahashi K, Yamazaki M, Ohtori S. Surgical correction of spinal deformity in patients with congenital muscular dystrophy. *J Orthop Sci.* 2010;15:493–501. PubMed PMID: 20721717.
- Taniguchi K, Kobayashi K, Saito K, Yamanouchi H, Ohnuma A, Hayashi YK, Many H, Jin DK, Lee M, Parano E, Falsaperla R, Pavone P, Van Coster R, Talim B, Steinbrecher A, Straub V, Nishino I, Topaloglu H, Voit T, Endo T, Toda T. Worldwide distribution and broader clinical spectrum of muscle-eye-brain disease. *Hum Mol Genet.* 2003;12:527–34. PubMed PMID: 12588800.
- Taniguchi M, Kurahashi H, Noguchi S, Sese J, Okinaga T, Tsukahara T, Guicheney P, Ozono K, Nishino I, Morishita S, Toda T. Expression profiling of muscles from Fukuyama-type congenital muscular dystrophy and laminin- α -2 deficient congenital muscular dystrophy; is congenital muscular dystrophy a primary fibrotic disease? *Biochem Biophys Res Commun.* 2006;342:489–502. PubMed PMID: 16487936.
- Taniguchi-Ikeda M, Kobayashi K, Kanagawa M, Yu C, Mori K, Oda T, Kuga A, Kurahashi H, Akman HO, DiMauro S, Kaji R, Yokota T, Takeda S, Toda T. Pathogenic exon-trapping by SVA retrotransposon and rescue in Fukuyama muscular dystrophy. *Nature.* 2011;478:127–31. PubMed PMID: 21979053.
- Taniguchi-Ikeda M, Morioka I, Iijima K, Toda T. Mechanistic aspects of the formation of α -dystroglycan and therapeutic research for the treatment of α -dystroglycanopathy: a review. *Mol Aspects Med.* 2016;51:115–24. PubMed PMID: 27421908.
- Tsutsumi A, Uchida Y, Osawa M, Fukuyama Y. Ocular findings in Fukuyama type congenital muscular dystrophy. *Brain Dev.* 1989;11:413–9. PubMed PMID: 2618965.
- Vannoy CH, Xiao W, Lu P, Xiao X, Lu QL. Efficacy of gene therapy is dependent on disease progression in dystrophic mice with mutations in the FKRP gene. *Mol Ther Methods Clin Dev.* 2017;5:31–42. PubMed PMID: 28480302.
- Voglmeir J, Kaloo S, Laurent N, Meloni MM, Bohlmann L, Wilson IB, Flitsch SL. Biochemical correlation of activity of the α -dystroglycan-modifying glycosyltransferase POMGnT1 with mutations in muscle-eye-brain disease. *Biochem J.* 2011;436:447–55. PubMed PMID: 21361872.
- Vuillaumier-Barrot S, Quijano-Roy S, Bouchet-Seraphin C, Maugendre S, Peudenier S, Van den Bergh P, Marcorettes P, Avila-Smirno D, Chelbi M, Romero NB, Carlier RY, Estournet B, Guicheney P, Seta N. Four Caucasian patients with mutations in the fukutin gene and variable clinical phenotype. *Neuromusc Disord.* 2009;19:182–8. PubMed PMID: 19179078.
- Wang CH, Bonnemann CG, Rutkowski A, Sejersen T, Bellini J, Battista V, Florence JM, Schara U, Schuler PM, Wahbi K, Aloysius A, Bash RO, Bérout C, Bertini E, Bushby K, Cohn RD, Connolly AM, Deconinck N, Desguerre I, Eagle M, Estournet-Mathiaud B, Ferreira A, Fujak A, Goemans N, Iannaccone ST, Jouinot P, Main M, Melacini P, Mueller-Felber W, Muntoni F, Nelson LL, Rahbek J, Quijano-Roy S, Sewry C, Storhaug K, Simonds A, Tseng B, Vajsar J, Vianello A, Zeller R, et al. Consensus statement on standard of care for congenital muscular dystrophies. *J Child Neurol.* 2010;25:1559–81. PubMed PMID: 21078917.
- Watanabe M, Kobayashi K, Jin F, Park KS, Yamada T, Tokunaga K, Toda T. Founder SVA retrotransposal insertion in Fukuyama-type congenital muscular dystrophy and its origin in Japanese and Northeast Asian populations. *Am J Med Genet A.* 2005;138:344–8. PubMed PMID: 16222679.
- Xu L, Lu PJ, Wang CH, Keramaris E, Qiao C, Xiao B, Blake DJ, Xiao X, Lu QL. Adeno-associated virus 9 mediated FKRP gene therapy restores functional glycosylation of α -dystroglycan and improves muscle functions. *Mol Ther.* 2013;21:1832–40. PubMed PMID: 23817215.
- Yamamoto T, Taniguchi-Ikeda M, Awano H, Matsumoto M, Lee T, Harada R, Imanishi T, Hayashi N, Sakai Y, Morioka I, Takeshima Y, Iijima K, Saegusa J, Toda T. Cardiac involvement in Fukuyama muscular dystrophy is less severe than in Duchenne muscular dystrophy. *Brain Dev.* 2017;39:861–8. PubMed PMID: 28578814.

- Yang H, Kobayashi K, Wang S, Jiao H, Xiao J, Toda T, Wu X, Xiong H. Founder mutation causes classical Fukuyama congenital muscular dystrophy (FCMD) in Chinese patients. *Brain Dev.* 2015;37:880–6. PubMed PMID: 25814170.
- Yis U, Uyanik G, Heck PB, Smitka M, Nobel H, Ebinger F, Dirik E, Feng L, Kurul SH, Brocke K, Unalp A, Özer E, Cakmakci H, Sewry C, Cirak S, Muntoni F, Hehr U, Morris-Rosendahl DJ. Fukutin mutations in non-Japanese patients with congenital muscular dystrophy: less severe mutations predominate in patients with a non-Walker-Warburg phenotype. *Neuromuscul Disord.* 2011;21:20–30. PubMed PMID: 20961758.
- Yoshioka M. Phenotypic spectrum of fukutinopathy: most severe phenotype of fukutinopathy. *Brain Dev.* 2009;31:419–22. PubMed PMID: 18834683.
- Yoshioka M, Higuchi Y, Fujii T, Aiba H, Toda T. Seizure-genotype relationship in Fukuyama-type congenital muscular dystrophy. *Brain Dev.* 2008;30:59–67. PubMed PMID: 17597323.
- Yoshioka M, Kobayashi K, Toda T. Novel FKRP mutations in a Japanese MDC1C sibship clinically diagnosed with Fukuyama congenital muscular dystrophy. *Brain Dev.* 2017;39:869–72. PubMed PMID: 28629604.

License

GeneReviews® chapters are owned by the University of Washington. Permission is hereby granted to reproduce, distribute, and translate copies of content materials for noncommercial research purposes only, provided that (i) credit for source (<http://www.genereviews.org/>) and copyright (© 1993-2024 University of Washington) are included with each copy; (ii) a link to the original material is provided whenever the material is published elsewhere on the Web; and (iii) reproducers, distributors, and/or translators comply with the [GeneReviews® Copyright Notice and Usage Disclaimer](#). No further modifications are allowed. For clarity, excerpts of GeneReviews chapters for use in lab reports and clinic notes are a permitted use.

For more information, see the [GeneReviews® Copyright Notice and Usage Disclaimer](#).

For questions regarding permissions or whether a specified use is allowed, contact: admasst@uw.edu.