



Incontinentia Pigmenti

Synonym: Bloch-Sulzberger Syndrome

Angela E Scheuerle, MD, FAAP, FACMG¹ and Matilde Valeria Ursini, PhD²

Created: June 8, 1999; Updated: December 21, 2017.

Summary

Clinical characteristics

Incontinentia pigmenti (IP) is a disorder that affects the skin, hair, teeth, nails, eyes, and central nervous system; it occurs primarily in females and on occasion in males. Characteristic skin lesions evolve through four stages:

- I. Blistering (birth to age ~4 months)
- II. Wart-like rash (for several months)
- III. Swirling macular hyperpigmentation (age ~6 months into adulthood)
- IV. Linear hypopigmentation

Alopecia, hypodontia, abnormal tooth shape, and dystrophic nails are observed. Neovascularization of the retina, present in some individuals, predisposes to retinal detachment. Neurologic findings including seizures, intellectual disability, and developmental delays are occasionally seen.

Diagnosis/testing

The diagnosis of IP is established in a proband with at least one major criterion (characteristic skin lesion). Identification of a heterozygous *IKBKG* pathogenic variant in a female proband or a hemizygous *IKBKG* pathogenic variant in a male proband confirms the diagnosis if clinical features are inconclusive.

Management

Treatment of manifestations: Standard management of blisters and skin infections; dental care by a pedodontist; dental implants in childhood as needed; care by a speech pathologist and/or pediatric nutritionist if dental abnormalities interfere with chewing and/or speech; cryotherapy and laser photocoagulation of retinal neovascularization to reduce risk of retinal detachment; standard management of retinal detachment; referral to a pediatric neurologist for management of seizures, spasticity, or focal deficits; brain MRI for functional

Author Affiliations: 1 Division of Genetics and Metabolism, Department of Pediatrics, University of Texas Southwestern Medical Center, Dallas, Texas; Email: angela.scheuerle@utsouthwestern.edu. 2 Department of Molecular and Human Genetics, Institute of Genetics and Biophysics, National Research Council, Naples, Italy; Email: ursini@igb.cnr.it.

neurologic abnormalities and/or retinal neovascularization; developmental programs and special education as needed for developmental delay.

Prevention of secondary complications: Standard measures to reduce the risk of skin infection; evaluate for retinal detachment if vision decreases, strabismus appears, or head trauma occurs.

Surveillance: Eye examination: monthly until age four months, then every three months from age four months to one year, every six months from age one to three years, and annually after age three years. Assessment of neurologic function at routine visits with pediatrician, pediatric neurologist, or developmental pediatrician; routine evaluation by a pedodontist or dentist.

Evaluation of relatives at risk: Identification of affected relatives by physical examination and retinal examination so that screening ophthalmology examinations can be performed.

Genetic counseling

IP is inherited in an X-linked manner. About 65% of affected individuals have IP as a result of a *de novo* pathogenic variant. Heterozygous, affected women have a 50% chance of transmitting the *IKBKG* pathogenic variant at conception; however, male conceptuses with an *IKBKG* loss-of-function variant miscarry. Thus, the expected ratio among live-born children of a mother with IP is approximately 33% unaffected females, 33% affected females, and 33% unaffected males. To date, all males with IP have had either a 47,XXY karyotype or somatic mosaicism for the *IKBKG* pathogenic variant. A male with somatic and germline mosaicism may transmit the *IKBKG* pathogenic variant to daughters (females who inherit the pathogenic variant will be affected); an affected male would not transmit an *IKBKG* pathogenic variant to sons. Prenatal testing for pregnancies at increased risk and preimplantation genetic testing are possible if the familial pathogenic variant has been identified.

Diagnosis

Suggestive Findings

Incontinentia pigmenti (IP) **should be suspected** in individuals with characteristic clinical findings of the skin, teeth, hair, nails, eyes, and CNS, and family history as detailed below.

Major criteria (skin lesions that occur in stages from infancy to adulthood)

- **Erythema** followed by blisters (vesicles) anywhere on the body except the face, usually in a linear distribution. The blisters clear within weeks and may be replaced by a new crop. Erythema occurs in stage I (first weeks of life to age 24 months; most prominent before age 6 months)
- **Verrucous lesions** that respect Blaschko lines, occurring mainly on the limbs; stage II (first weeks of life to 24 months)
- **Hyperpigmented streaks and whorls** that respect Blaschko lines, occurring mainly on the trunk and fading in adolescence; stage III (age 4 months to 16 years, rarely persisting into adulthood)
- **Pale, hairless, atrophic linear streaks** or patches; stage IV (adolescence through adulthood)

Note: Though the lesions classically occur in the indicated stages, more than one type of lesion may be present at any time. The locations of the lesions can vary from stage to stage.

Minor criteria

- **Teeth.** Hypodontia or anodontia (partial or complete absence of teeth), microdontia (small teeth), abnormally shaped teeth
- **Hair.** Alopecia, woolly hair (lusterless, wiry, coarse)

- **Nails.** Mild ridging or pitting; onychogryposis (hypertrophied, curved nails)
- **Retina.** Peripheral neovascularization
- **Family history** consistent with X-linked inheritance or a history of multiple miscarriages

Note: (1) The presence of minor criteria supports the clinical diagnosis. (2) Minić et al [2014] have suggested that CNS, palate, and nipple/breast anomalies be added to the minor diagnostic criteria.

Establishing the Diagnosis

The diagnosis of IP is **established** in a proband if at least one of the major criteria is present. If clinical features are inconclusive, the diagnosis of IP can be established by identification of one of the following by molecular genetic testing:

- A heterozygous *IKBKG* pathogenic (or likely pathogenic) variant in a female proband
- A hemizygous *IKBKG* pathogenic variant in a male proband
- Mosaicism for an *IKBKG* pathogenic variant in a male proband (see Table 1)

Note: (1) Per ACMG/AMP variant interpretation guidelines, the terms "pathogenic variants" and "likely pathogenic variants" are synonymous in a clinical setting, meaning that both are considered diagnostic and both can be used for clinical decision making [Richards et al 2015]. Reference to "pathogenic variants" in this section is understood to include any likely pathogenic variants. (2) The identification of variant(s) of uncertain significance cannot be used to confirm or rule out the diagnosis.

The most efficacious molecular genetic testing approach is **single-gene testing**.

Single-gene testing. Targeted analysis for the common 11.7-kb *IKBKG* deletion can be performed first or concurrently with sequence analysis of *IKBKG* followed by gene-targeted deletion/duplication analysis if no pathogenic variant is found.

Note: Analysis of *IKBKG* is complicated by the presence of a highly homologous pseudogene, *IKBKGPI*. For more information on pseudogenes, click [here](#).

Note: In affected males, somatic mosaicism can result in failure to detect an *IKBKG* loss-of-function pathogenic variant. For this reason, molecular genetic testing of a tissue sample (e.g., skin from an affected site, sperm), may be needed if no pathogenic variant is identified by molecular genetic testing of a blood sample.

A multigene panel that includes *IKBKG* and other genes of interest (see Differential Diagnosis) may be considered. Note: (1) Methods used in a panel may include sequence analysis, deletion/duplication analysis, and/or other non-sequencing-based tests. In the case of *IKGKG*, sequencing methods other than NGS must be employed due to the presence of *IKBKGPI*. (2) The genes included in the panel and the diagnostic sensitivity of the testing used for each gene vary by laboratory and are likely to change over time. (3) Some multigene panels may include genes not associated with the condition discussed in this *GeneReview*; thus, clinicians need to determine which multigene panel is most likely to identify the genetic cause of the condition while limiting identification of variants of uncertain significance and pathogenic variants in genes that do not explain the underlying phenotype. (4) In some laboratories, panel options may include a custom laboratory-designed panel and/or custom phenotype-focused exome analysis that includes genes specified by the clinician. (5) Methods used in a panel may include sequence analysis, deletion/duplication analysis, and/or other non-sequencing-based tests.

For an introduction to multigene panels click [here](#). More detailed information for clinicians ordering genetic tests can be found [here](#).

Table 1. Molecular Genetic Testing Used in Incontinentia Pigmenti

Gene ¹	Method	Proportion of Proband with a Pathogenic Variant ² Detectable by Method	
		Females	Males
<i>IKBKG</i>	Targeted analysis for ~11.7-kb common deletion (c.399-?_1260+?del)	~65% ³	3/18 (16%) ⁴
	Sequence analysis ⁵	~8.6% ⁴	2 individuals ⁶
	Gene-targeted deletion/duplication analysis ⁷	~4% ⁸	None reported
Unknown ⁹	NA		

1. See Table A. Genes and Databases for chromosome locus and protein.

2. See Molecular Genetics for information on variants detected in this gene.

3. Fusco et al [2008]

4. Three of 18 males with IP with somatic mosaicism for the common 11.7-kb deletion [Fusco et al 2007]

5. Sequence analysis detects variants that are benign, likely benign, of uncertain significance, likely pathogenic, or pathogenic. Variants may include small intragenic deletions/insertions and missense, nonsense, and splice site variants; typically, exon or whole-gene deletions/duplications are not detected. For issues to consider in interpretation of sequence analysis results, click [here](#).

6. Fusco et al [2017] reported a male with IP with somatic mosaicism for the c.394C>T pathogenic variant. Chang et al [2008] reported a male with the pathogenic variant c.1167dupC (also known as 1167insC); he is the only male known to have both HED-ID (hypohidrotic ectodermal dysplasia and immunodeficiency) and the skin findings of IP (see Genetically Related Disorders).

7. Gene-targeted deletion/duplication analysis detects locus-specific deletions or duplications. Methods used may include a range of techniques such as quantitative PCR, long-range PCR, and Southern blotting. Assay designs must account for presence of the *IKBKG* pseudogene.

8. Quantitative PCR analysis of *IKBKG* locus to evaluate partial copy number loss or copy number gain along the locus revealed pathogenic variants due to aberrant recombination in the locus producing deletions involving *IKBKG*, the *IKBKG* pseudogene, and eventually the neighboring gene *G6PD* [Fusco et al 2012, Conte et al 2014].

9. Although no evidence of additional loci causing IP has been reported, there remain 4.7% of individuals with IP who have no pathogenic variant in the *IKBKG* locus assigned. For them locus heterogeneity cannot be excluded [Fusco et al 2014].

Skin biopsy for histopathology can be considered in affected individuals in whom an *IKBKG* pathogenic variant is not identified on molecular genetic testing.

- **Affected females.** Identification of eosinophilic infiltration and/or extracellular melanin granules on histologic examination of a skin biopsy can suggest or confirm the diagnosis in females with characteristic clinical features, but is now rarely needed given the widespread availability and sensitivity of molecular genetic testing (see Table 1). Nonetheless, skin biopsy may be helpful in confirming the diagnosis in a female with borderline or questionable findings in whom molecular genetic testing has not identified a pathogenic variant.
- **Affected males.** Histologic examination of skin biopsy may be more helpful in males, particularly when mosaicism is being considered. Routine pathologic examination may be done on the same biopsy used for molecular genetic testing.

Clinical Characteristics

Clinical Description

Incontinentia pigmenti (IP) is a disorder of the skin and its appendages, eye, and central nervous system (CNS) that occurs primarily in females and on occasion in males.

The largest cohort of individuals with IP in whom the clinical and molecular diagnosis has been confirmed is reported in Fusco et al [2014].

Skin. See Figure 1, Figure 2, Figure 3, and Figure 4. IP manifests in stages that evolve sequentially. The onset and duration of each stage vary among individuals, and not all individuals experience all four stages. The skin abnormalities that define each stage occur along lines of embryonic and fetal skin development known as Blaschko lines (see Figure 3). Blaschko lines correspond with cell migration or growth pathways that are established during embryogenesis. Like dermatomes, they are linear on the limbs and circumferential on the trunk. Unlike dermatomes, Blaschko lines do not correspond to innervation patterns or spinal cord levels.

- **Stage I – bullous stage** is characterized by blister-like bullous eruptions (Figure 1) that are linear on the extremities and/or circumferential on the trunk. The eruptions can be erythematous and may appear infectious. Stage I manifests within the first six to eight weeks and can be present at birth. The stage I rash generally disappears by age 18 months, although a vesicobullous eruption was reported in a girl age five years who was already manifesting the stage IV rash [Darné & Carmichael 2007].
- **Stage II – verrucous stage** is characterized by a hypertrophic, wart-like rash that is linear on the extremities and/or circumferential on the trunk (see Figure 2). This stage manifests within the first few months of life. It can occasionally be present at birth but typically arises as stage I begins to resolve. Stage II usually lasts for a few months, but it can last for years. Stage II can also include the appearance of dystrophic nails and abnormalities of tooth eruption.
- **Stage III – hyperpigmentation stage** is characterized by macular, slate gray, or brown hyperpigmentation that occurs in a "marble cake" or swirled pattern along Blaschko lines, usually circumferential on the trunk and linear on the extremities (see Figure 3). The hyperpigmentation stage is the most characteristic stage for IP. Not all women have extensive hyperpigmentation; it can be quite limited. The most frequently involved areas are the groin and axilla. The entire skin surface may need to be examined to find characteristic patterns. Hyperpigmentation begins between age six months and one year, usually as stage II begins to resolve. It is NOT present at birth. Stage III can persist into adulthood. The hyperpigmentation usually begins to fade in the teens and early twenties (see Figure 4). The pigmentation changes can be linear, swirled, or reticulated. A woman in her thirties or later may show no skin changes associated with IP.
- **Stage IV – atretic stage** is characterized by linear *hypopigmentation* and alopecia, particularly noticeable on the extremities and, when it happens, on the scalp. The definition of stage IV remains open. There may not be true hypopigmentation, but rather a loss of hair and epidermal glands. As with the first three stages, the pattern follows Blaschko lines. Stage IV does not occur in all individuals. When present, it arises after the hyperpigmentation fades.

Hair. Alopecia may occur on the scalp and also on the trunk and extremities. Patchy alopecia of the scalp may correspond to areas of scarring left from blistering in stage I, but may also occur in individuals who have had no stage I or II lesions on the scalp. Alopecia occurs in areas of skin hypopigmentation as part of stage IV skin changes. Scalp hair may be thin or sparse in early childhood. Hair may also be lusterless, wiry, and coarse, often at the vertex in a "woolly-hair nevus." Areas of alopecia may be very small, unnoticed by the affected individual and difficult to find, particularly when covered by other scalp hair. Sparse eyelashes and eyebrows are also reported.

Teeth. Abnormalities include hypodontia (too few teeth), microdontia (small teeth), abnormally shaped teeth (e.g., conical teeth or accessory cusps), delayed eruption, or impaction. Enamel and tooth strength are normal. The tooth anomalies reported in individuals with IP are widely variable and may be said to encompass virtually any aberration in tooth shape and/or number.

Nails. Nails can be dystrophic (i.e., lined, pitted, or brittle). These changes often resemble fungal infections of the nails. Dystrophic nails are most commonly associated with stage II. The nail changes may be transient, but a single, chronic, longitudinal ridge in the nail was present in 28% of persons in one study [Phan et al 2005].

Ophthalmologic. Individuals with IP are at increased risk (20%-77%) for ophthalmologic abnormalities.

- **Retinal** hypervascularization is most common. When untreated, this leads to retinal detachment. The greatest risk for retinal detachment is in infancy and childhood; it almost never occurs after age six years. The changes are visible on indirect ophthalmoscopy through a dilated pupil.
- **Other eye findings** include strabismus, cataracts, optic atrophy, retinal pigmentary abnormalities, and microphthalmia [Meuwissen & Mancini 2012, Fusco et al 2014].

Central nervous system. Seizures, intellectual disability, and other CNS abnormalities have been reported in approximately 30% of individuals with IP [Minić et al 2014]. The actual incidence of neurocognitive disability is unclear because mildly affected individuals without neurocognitive problems may not come to medical attention [Phan et al 2005]. Neurocognitive disability is more common in simplex than in familial cases, presumably because mildly affected family members are identified. Males with IP are more likely than females to have neurologic abnormalities. In general, neurologic abnormalities in individuals with IP appear to be associated with underlying CNS vasculopathy [Meuwissen & Mancini 2012].

- **Seizures.** Seizures in IP range from a single episode in a lifetime to chronic epilepsy. The type of seizure varies because the stroke etiology may involve any part of the cerebrum. In the review of well-documented individuals with IP who have neurocognitive disability, Meuwissen & Mancini [2012] note that of seizure types reported, focal clonic seizures were the most frequently observed. Of all affected persons with neurocognitive problems, about 25% experience one or more seizures (i.e., ~7% of all individuals diagnosed with IP). The vast majority of seizures manifest within the first year of life (32 of 35 individuals with seizures where onset was reported). Fourteen of 25 individuals in whom recurrence was reported experienced only one seizure [Meuwissen & Mancini 2012].
- **Intellect.** Available studies of cognitive function in IP are limited. There is a range of function, including normal. Severe intellectual disability is not common. In males, co-occurrence of a 47,XXY karyotype may complicate the intellectual phenotype of IP.

Pizzamiglio et al [2014] reported a group of ten females with IP who were underwent cognitive assessment. Seven of the ten had deficits in calculation / arithmetic reasoning and reading but not writing skills. This evaluation makes it possible to place "learning disabilities" among the manifestations of IP. A follow-up study in 2017 [Pizzamiglio et al 2017] showed that nine of 14 girls had normal development while five had intellectual disabilities ranging from mild to severe.

- **Brain anomaly.** Primary brain anomalies are rare. The following have each been reported in separate affected individuals: agenesis of the corpus callosum with an occipital encephalocele [Demirel et al 2009]; polymicrogyria [Godambe et al 2005]; and gray matter heterotopias [Mangano & Barbagallo 1993]. Evidence that *IKBKG* pathogenic variants may cause abnormalities in microvasculature supports the theory that CNS dysfunction is secondary to vascular problems that result in transient ischemic attacks or full-blown hemorrhagic strokes [Fiorillo et al 2003, Hennel et al 2003, Shah et al 2003]. Neurovascular abnormalities are most common in the first year of life, with only a handful of individuals reported after that, and only three after age four years [Meuwissen & Mancini 2012].
- Periventricular leukomalacia was identified on brain MRI in 27 of 43 individuals with IP who have neurocognitive disabilities, especially seizures, and subcortical white matter changes were also seen commonly. Some individuals have subsequent cystic changes. Myelination delays and ventricular dilatation have also been reported [Meuwissen & Mancini 2012].
- **Spastic paresis.** The frequency of this finding is unknown. It is difficult to interpret older literature findings. As with other neurologic abnormalities in IP, the risk and severity of spastic paresis appears to be related to CNS vasculopathy.

Breast. Abnormalities of mammary tissue ranging from aplasia of the breast to supernumerary nipples are variably present but are more common than in the general population [Minić et al 2014]. The recognized frequency of breast abnormalities may be limited because reports tend to focus on prepubertal children.

Other

- **Leukocytosis** with up to 65% eosinophils may occur, particularly in stages I and II. The specific cause of the leukocytosis is unknown. Zilberman-Rudenko et al [2016] note that pathogenic variants in *IKBKG* impair suppression of NF- κ B, leading to hyperactive reactive inflammatory response. Eosinophilia is not consistently associated with any clinical manifestations and typically resolves spontaneously.
- **Primary pulmonary hypertension** has been reported in some individuals and is presumably related to vasculopathy [Alshenqiti et al 2017].

Males with IP. Although IP has been identified as a "male-lethal" disease, there are well-documented affected males. There are a few individual case reports published each year and intermittent reviews of the literature.

Survival in a male is mediated through one of two mechanisms:

- 47,XXY karyotype, estimated to be present in 7% of males with IP [Pacheco et al 2006]
- Somatic mosaicism
 - Low-level mosaicism of 46,XY/47,XXY was demonstrated in one male only by interphase FISH using X and Y probes [Franco et al 2006]. The affected child did not have a demonstrable *IKBKG* pathogenic variant.
 - Low-level mosaicism for an *IKBKG* loss-of-function pathogenic variant was identified in two males; fibroblast and sperm DNA contained the highest percentage of abnormal cells [Fusco et al 2017].
 - Some males also exhibit "segmental" IP (lesions restricted to a single limb), a finding consistent with somatic mosaicism.

The reasoning behind male lethality in IP is that male conceptuses that inherit an X chromosome with a mutated *IKBKG* gene lack the normal protein necessary for viability. The precise mechanism of male lethality is unknown [Hatchwell 1996], although mouse models suggest that liver failure plays a role [Rudolph et al 2000].

Pathogenic variants that produce a milder form of the condition are always associated with immunodeficiency, known as X-linked hypohidrotic ectodermal dysplasia and immunodeficiency (HED-ID), in males [Fusco et al 2008]. Only one male has been reported with HED-ID and also clinical findings of IP in association with the c.1167dupC *IKBKG* variant [Chang et al 2008].

Life expectancy. For persons without significant neonatal or infantile complications, life expectancy is considered to be normal.

Reproductive fitness. Women with IP are at increased risk for pregnancy loss, presumably related to low viability of male fetuses. It is common for women with IP to experience multiple miscarriages, often around the third or fourth month of gestation. Fertility does not otherwise appear to be impaired; conception of an unaffected fetus would be expected to result in an uncomplicated pregnancy and delivery.

Genotype-Phenotype Correlations

A group of pathogenic variants (mainly located in exon 10) that result in impaired but not absent NF-kappaB signaling [Fusco et al 2008] are associated with a milder IP phenotype in females and a lower risk of miscarriage of male fetuses. Additionally, most of these variants (which include missense, single base insertion/deletion causing frameshift, and nonsense variants) allow survival of males with hypohidrotic ectodermal dysplasia and immunodeficiency (HED-ID) and anhidrotic ectodermal dysplasia with immunodeficiency, osteopetrosis, and lymphedema (OLEDAID) (see Genetically Related Disorders).

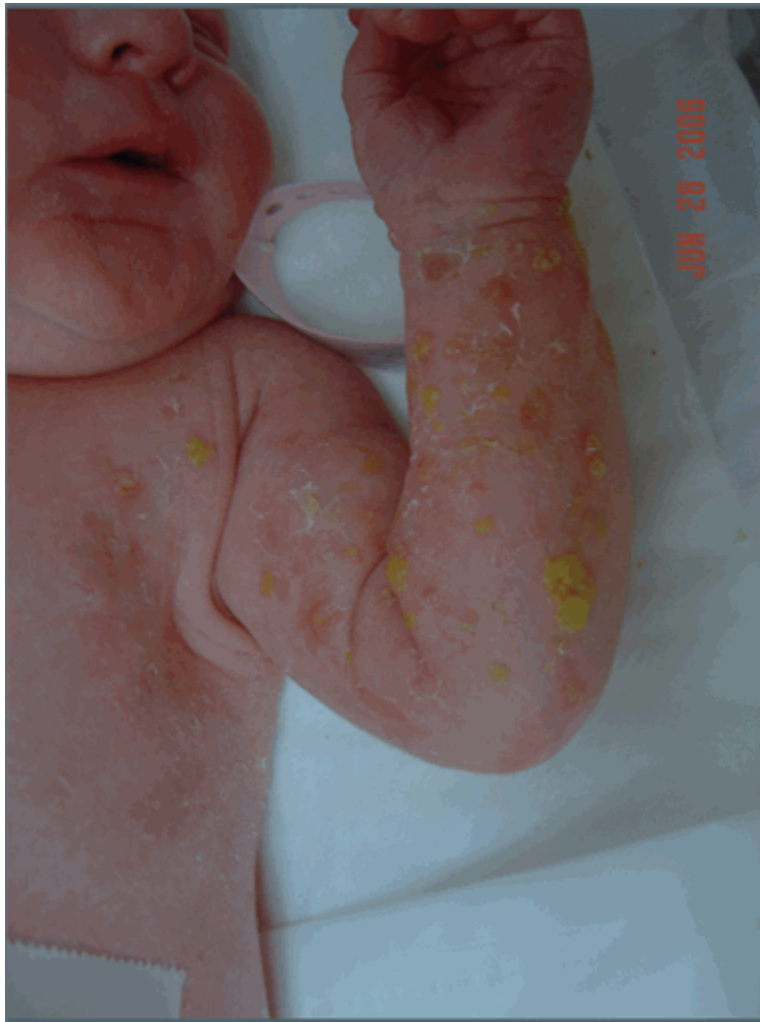

Figure 1. IP in an affected female; stage I: the bullous ("blistering") stage. Note that the blisters are not necessarily linear.

Penetrance

Incontinentia pigmenti has high penetrance. Most persons with IP appear to express the phenotype within a few months after birth.

Expressivity, however, is highly variable. In addition, the skin findings can resolve over time and may be indistinguishable from other skin conditions with age. Furthermore, the dental, hair, and nail abnormalities can be managed cosmetically such that an affected adult woman may not have clinically evident diagnostic findings on physical examination.

Nomenclature

Some individuals with structural abnormalities of the X chromosome manifest swirled hyperpigmentation even though their X-chromosome abnormalities do not involve the *IKBKG* locus (Xq28). This observation led to the designation of a separate condition, incontinentia pigmenti type I (IP type I), with a suggested locus at Xp11. Detailed research failed to document consistent linkage to Xp11 or a consistent phenotype. Thus, the designation "IP type I" is thought to be incorrect [Happle 1998].

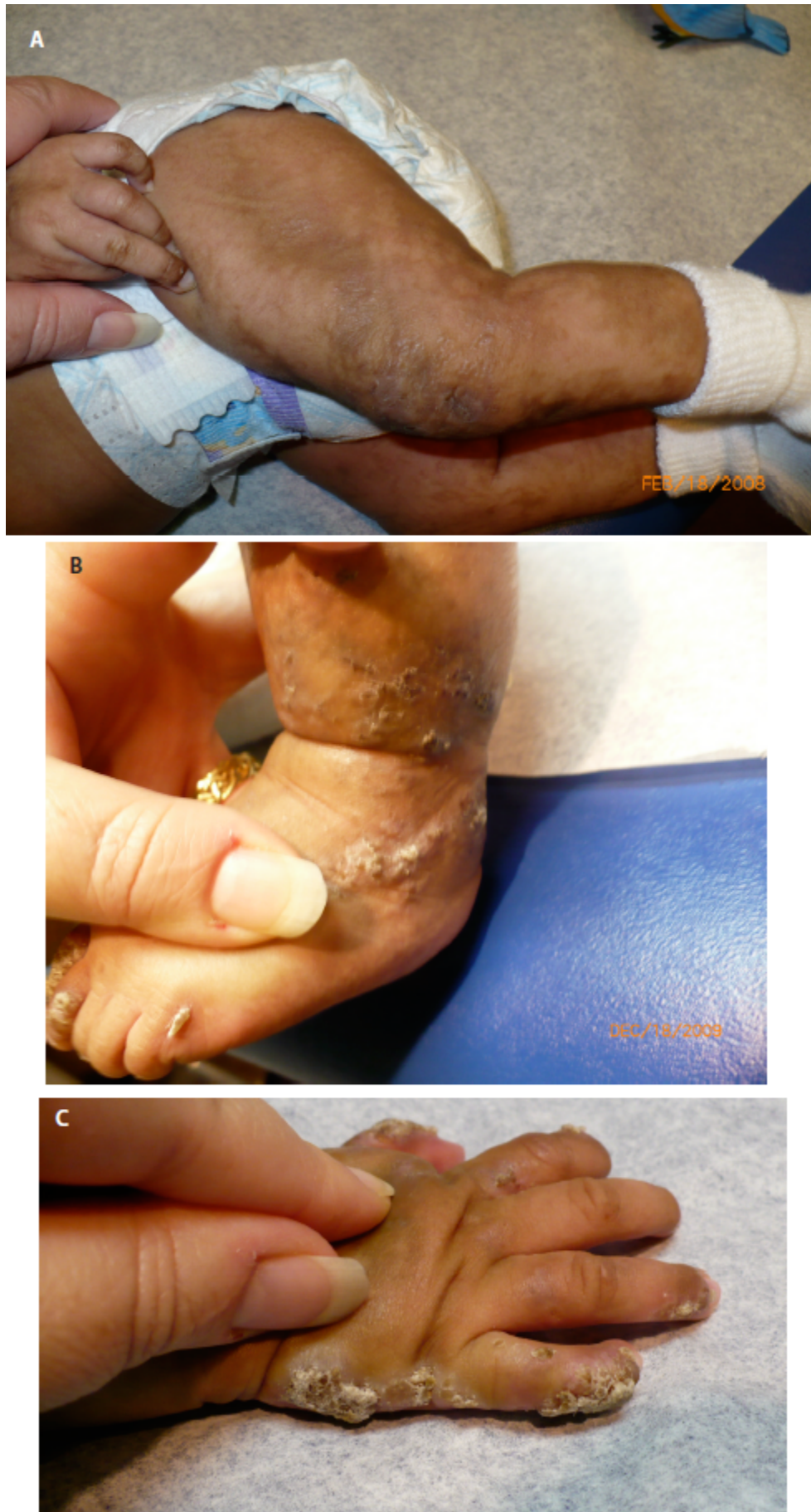


Figure 2. IP in an affected female; stage II: the verrucous ("warty") stage. The lesions do not necessarily arise in the same place as those

of stage I.

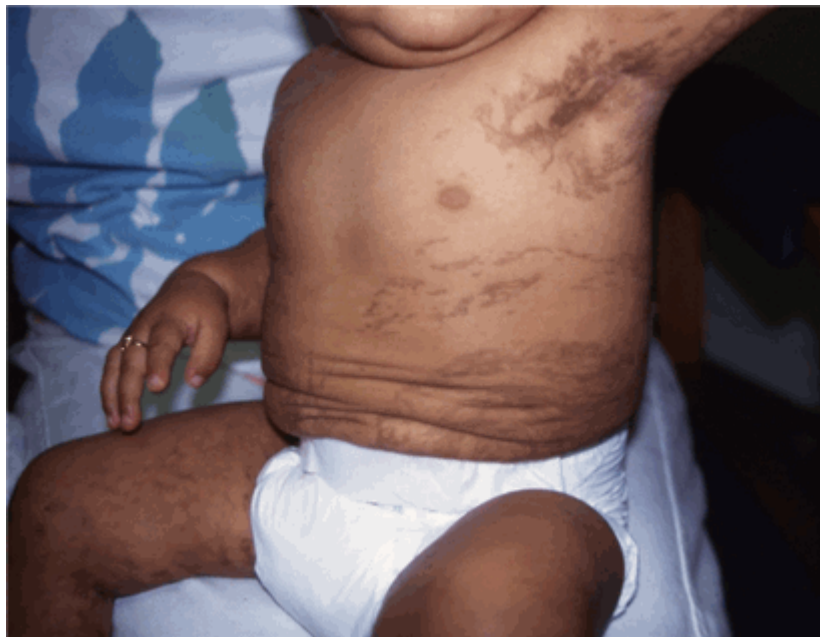

Figure 3. IP in an affected female with stage III "rash"

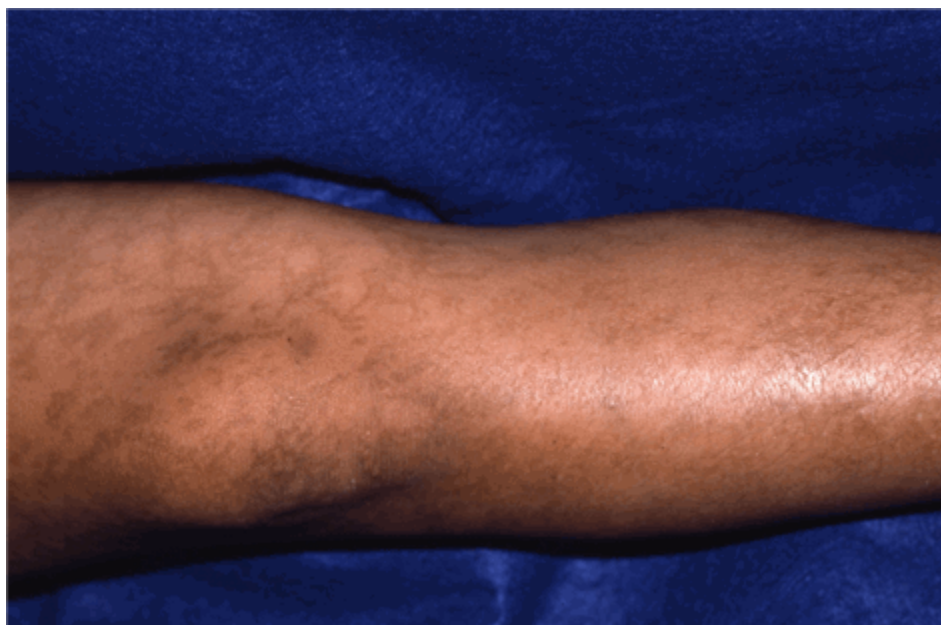


Figure 4. An adult with reticulated pigmentation patterns

Prevalence

More than 2,000 females with IP have been reported [Minić et al 2014]. The number of reported females and males continues to grow, especially with further delineation of the underlying molecular mechanisms. Public health birth defect surveillance systems put the birth prevalence of IP at 0.6–0.7/1,000,000 [Orphanet, Texas

Birth Defects Registry, Unpublished data]. The female:male ratio is 20:1 [Orphanet Report Series 2017]. Orphanet recently estimated prevalence at birth of 1.2/100,000 in the European Union.

Genetically Related (Allelic) Disorders

Hypohidrotic ectodermal dysplasia and immunodeficiency (HED-ID) (OMIM 300291) and **anhidrotic ectodermal dysplasia with immunodeficiency, osteopetrosis, and lymphedema (OLEDAID)** (OMIM 300301) affect males exclusively. They are caused primarily by missense variants (although in-frame deletions, frameshifts, and splicing and other pathogenic variants are known) within *IKBKG* that result in impaired, but not absent, nuclear factor-kappaB (NF-kappaB) signaling. A list of the *IKBKG* pathogenic variants associated with HED-ID has been reported [Fusco et al 2008]. Note: HED-ID and OLEDAID are distinct from the X-linked form of hypohidrotic ectodermal dysplasia that is caused by pathogenic variants in or deletion of *EDA* (see [Hypohidrotic Ectodermal Dysplasia](#)).

Immunodeficiency 33 / X-linked mycobacteriosis (IMD33, AMCBX1) (OMIM 300636) manifests as combined immunodeficiency with early susceptibility to pyogenic bacteria and later susceptibility to mycobacterial infection. This was reported in association with particular *IKBKG* pathogenic variants in males.

Differential Diagnosis

A diagnosis other than incontinentia pigmenti (IP) should be considered when an individual has skeletal involvement (other than secondary to neurologic deficit), gross neurologic deficit, severe alopecia, atypical hyperpigmentation, or gross hypopigmentation. Body segment asymmetry is not usually associated with IP; however, one individual with IP and transverse terminal upper acromelia has been reported [Hayes et al 2005].

The differential diagnosis for the skin manifestations of IP varies by stage. Because a child with IP may have an infectious comorbidity, findings consistent with an infectious disease should be evaluated accordingly, regardless of the presence of IP.

- **Stage I – bullous stage.** The following need to be considered: congenital herpes simplex, varicella, staphylococcal or streptococcal bullous impetigo, and (in severe cases) epidermolysis bullosa (see [Dystrophic Epidermolysis Bullosa, Epidermolysis Bullosa Simplex](#)). The infectious conditions are typically associated with other signs of inflammation including fever and symptoms of systemic toxicity. Scrapings and cultures of the lesions are diagnostic for the infectious diseases. Blistering lesions that appear after light trauma are characteristic of epidermolysis bullosa. Diagnosis is established by analysis of a skin biopsy, transmission electron microscopy or immunofluorescent antibody/antigen mapping, and molecular genetic testing.
- **Stage II – verrucous stage.** The findings are not likely to be confused with other conditions, although an individual with mild IP may have skin findings that resemble simple warts or molluscum contagiosum. When the lesions are numerous and appear in the appropriate pattern, they are more likely to be IP than either warts or molluscum contagiosum. Differentiating single IP lesions from warts can be difficult without a biopsy.
- **Stage III – hyperpigmentation stage.** The differential diagnosis includes any condition that leads to irregular areas of skin pigmentation or other anomalies along the lines of Blaschko.

Linear and whorled pigmentation changes are a frequent finding in mosaic chromosome abnormalities. Individuals with chromosomal mosaicism often have intellectual disability and congenital malformations, including brain anomalies and the pigmentation abnormalities are present from birth without preceding rashes. Routine karyotyping on blood and/or skin (fibroblast) sample should be considered in these

individuals. Hypomelanosis of Ito (OMIM 300337) is a phenotype related to chromosomal mosaicism. Another important differentiation is that in individuals with IP the *hyperpigmented* areas are abnormal, whereas in hypomelanosis of Ito *hypopigmented* areas are abnormal. In individuals with chromosomal mosaicism, it can often be difficult to distinguish which pigmentation level is the "normal" for the individual.

- **Stage IV – atretic stage.** The atretic skin areas can resemble scarring, vitiligo (with localized alopecia), or any other condition demonstrating hypopigmentation and localized alopecia. Differentiation is based largely on medical history. Vitiligo is progressive and the hypopigmented areas can be surrounded by areas of hyperpigmentation. Vitiligo is not preceded by the other stages of IP or accompanied by non-cutaneous manifestations. Piebaldism (OMIM 172800), an autosomal dominant form of hypopigmentation in which manifestations are limited to the skin, is most often present at birth and does not progress.

The differential diagnosis of other manifestations of IP includes the following disorders:

- **Naegeli syndrome** (OMIM 161000), a rare autosomal dominant disorder affecting the skin and skin derivatives, resembles IP, but also includes hyperhidrosis and punctate hyperkeratosis of the palms and soles. Unlike IP, Naegeli syndrome does not evolve through different stages of skin involvement. Naegeli syndrome is extremely rare; an individual with linear, wart-like lesions is more likely to have IP. Pathogenic variants in *KRT14* cause Naegeli syndrome.
- **Retinal neovascularization** is observed in retinopathy of prematurity and familial exudative vitreoretinopathy, which can be inherited in an X-linked recessive manner as part of the Norrie disease spectrum (see [NDP-Related Retinopathies](#)) or in an autosomal dominant manner (see [Phenotypic Series: Exudative vitreoretinopathy](#)). Skin findings are not present in these disorders.

Management

Evaluations Following Initial Diagnosis

To establish the extent of disease and needs in an individual diagnosed with incontinentia pigmenti (IP), the following evaluations are recommended if they have not already been completed:

- Physical examination with particular emphasis on the skin, hair, nails, and neurologic system to establish the presence and extent of manifestations
- Consultation with a clinical geneticist and/or genetic counselor
- Involvement of a pediatric dermatologist for management of individuals with significant skin involvement
- Prompt examination by an ophthalmologist familiar with IP and/or diseases of the retina for evidence of retinal neovascularization
- Brain MRI examination and referral to a neurologist for an EEG if seizures, other neurologic abnormalities, or retinal hypervascularization are present
- Magnetic resonance angiography, potentially useful in identifying cerebrovascular lesions if the neurologic deficit is consistent with a stroke-like pattern
- Developmental evaluation if significant delays are identified
- Involvement of a pediatric cardiologist for management of neonates with pulmonary hypertension

Treatment of Manifestations

Treatment includes the following:

- Management of blisters in a standard manner (i.e., not opening them, avoiding trauma); topical treatment (e.g., medications, oatmeal baths) to relieve discomfort. Significant skin involvement may benefit from dermatology management.

- Treatment of infections as for any other cellulitis
- Referral to a pedodontist at age six months or when teeth erupt, whichever comes first. Dental implants have been performed as early as age seven years (as in children with ectodermal dysplasia, who have similar dental problems (see [Hypohidrotic Ectodermal Dysplasia](#)).
- Referral to a speech pathologist and/or pediatric nutritionist if delayed or inadequate eruption of primary teeth interferes with chewing and/or speech development
- For retinal neovascularization that predisposes to retinal detachment, cryotherapy and laser photocoagulation
- Standard treatment for retinal detachment
- Referral to a pediatric neurologist for treatment of seizures and if spasticity, focal deficits, or retinal hypervascularization are present
- Brain MRI in any child with functional neurologic abnormalities or retinal neovascularization
- Appropriate developmental stimulation and special education as indicated for developmental delay
- Standard management of neonatal pulmonary hypertension

Prevention of Secondary Complications

Management in the newborn period is aimed at reducing the risk of infection of blisters using standard medical management: not rupturing sealed blisters, keeping the areas clean while they are healing, and careful monitoring for excessive inflammation and signs of systemic involvement.

The parents should be instructed about the possibility of retinal detachment particularly in children younger than age seven years; any apparent changes in vision or any evidence of acquired strabismus should be evaluated promptly. Head trauma may precipitate retinal detachment; therefore, any evaluation for head trauma should include a thorough eye examination. There is currently no specific recommendation for avoidance of contact sports.

Surveillance

No schedule for eye examinations has been established, but the following has been suggested:

- Monthly until age three to four months
- Every three months between ages four months and one year
- Every six months between ages one and three years
- Annually after age three years

Neurologic function should be assessed at routine visits with a pediatrician, pediatric neurologist, or developmental pediatrician.

Ongoing evaluation by a pedodontist or dentist is appropriate.

Evaluation of Relatives at Risk

It is appropriate to evaluate apparently asymptomatic older and younger at-risk relatives of an affected individual in order to identify as early as possible those who would benefit from prompt initiation of treatment and preventive measures (routine eye examinations).

Evaluations can include:

- Molecular genetic testing if the pathogenic variant in the family is known;
- Physical examination including examination of the skin, teeth, hair, nails, retina, and neurologic assessment if the pathogenic variant in the family is not known.

See Genetic Counseling for issues related to testing of at-risk relatives for genetic counseling purposes.

Pregnancy Management

Overall pregnancy health and management usually does not vary from normal. The risk of spontaneous abortion related to fetal viability is higher than population rates, but management of pregnancy loss is done in the standard manner. For women with retinal problems, delivery management to minimize or eliminate labor should be considered to avoid retinal detachment.

Therapies Under Investigation

Search [ClinicalTrials.gov](https://clinicaltrials.gov) in the US and [EU Clinical Trials Register](https://clinicaltrialsregister.eu) in Europe for access to information on clinical studies for a wide range of diseases and conditions. Note: There may not be clinical trials for this disorder.

Genetic Counseling

Genetic counseling is the process of providing individuals and families with information on the nature, mode(s) of inheritance, and implications of genetic disorders to help them make informed medical and personal decisions. The following section deals with genetic risk assessment and the use of family history and genetic testing to clarify genetic status for family members; it is not meant to address all personal, cultural, or ethical issues that may arise or to substitute for consultation with a genetics professional. —ED.

Mode of Inheritance

Incontinentia pigmenti (IP) is inherited in an X-linked manner.

Risk to Family Members

Parents of a female proband

- A female with IP may have inherited the *IKBKG* pathogenic variant from her mother or may have a *de novo* pathogenic variant.
- When IP occurs as the result of a *de novo* pathogenic variant, the variant occurs more frequently in the *IKBKG* allele inherited from the father [Smahi et al 2000, Fusco et al 2004].
- *De novo* pathogenic variants in *IKBKG* are common: 59 (65%) of 91 females with IP and the common 11.7-kb deletion had a *de novo* pathogenic variant [Fusco et al 2009].
- If the mother meets the diagnostic criteria for IP or if she has an additional affected first-degree relative, she has a pathogenic variant in *IKBKG*.
- If the pathogenic variant in *IKBKG* has been identified in the proband, molecular genetic testing of the mother is warranted. Note: Because of the widely variable expressivity of the phenotype, adult women may be unaware of mild findings present during their own childhood and may, as adults, have no easily discernable physical findings.

Parents of a male proband

- If a male proband has IP as the result of mosaicism for a postzygotic *IKBKG* pathogenic variant, neither the mother nor the father is heterozygous or hemizygous, respectively, for the pathogenic variant.
- If a male proband has a 47,XXY karyotype, his mother may be heterozygous for an *IKBKG* pathogenic variant and molecular genetic testing of the mother is warranted [Kenwrick et al 2001].

Sibs of a female proband. The risk to sibs depends on the genetic status of the parents:

- **Mother of a female proband**

- If the mother of an affected female is also affected, the risk to sibs of inheriting the *IKBKG* pathogenic variant at conception is 50%; however, most male conceptuses with a loss-of-function variant in *IKBKG* miscarry. Thus, at delivery the expected ratio among offspring is approximately 33% unaffected females, 33% affected females, and 33% unaffected males.
- If the mother with IP has an *IKBKG* pathogenic variant that results in reduced (though not absent) protein activity, male conceptuses may survive and manifest anhidrotic ectodermal dysplasia with immunodeficiency (EDA-ID) at birth. Note: A mother with IP and the common 11.7-kb deletion (resulting in the complete absence of protein activity) is not at increased risk of having a live-born child with EDA-ID.
- **Father of a female proband.** If the father has somatic and germline mosaicism for an *IKBKG* pathogenic variant, all female sibs are at risk of inheriting the variant and being affected; male sibs are not at risk of inheriting the variant. Transmission of IP from fathers with somatic and germline mosaicism for *IKGKG* loss-of-function variants to daughters has been reported [Fusco et al 2017].
- If the proband represents a simplex case (i.e., a single occurrence in a family) and if the *IKBKG* pathogenic variant cannot be detected in the leukocyte DNA of either parent, the risk to sibs is slightly greater than that of the general population (though still <1%) because of the possibility of maternal or paternal germline mosaicism [Fusco et al 2017].

Sibs of a male proband. The risk to sibs depends on the genetic status of the mother (see **Sibs of a female proband**).

Offspring of a female proband (see Figure 5)

- The risk to the offspring of females with IP must take into consideration the presumed lethality to affected males during gestation (Figure 5).
- At conception, the risk that the *IKBKG* pathogenic variant will be transmitted is 50%; however, most male conceptuses with a loss-of-function variant in *IKBKG* miscarry. Thus, at delivery the expected ratio among offspring is approximately 33% unaffected females, 33% affected females, and 33% unaffected males.
- When a mother with IP has an *IKBKG* pathogenic variant that results in reduced (though not absent) protein activity, male conceptuses may survive and manifest EDA-ID at birth. Note: A mother with IP and the common 11.7-kb deletion (resulting in the complete absence of protein activity) is not at increased risk of having a live-born child with EDA-ID.

Offspring of a male proband

- To date, all males with IP have had either an 47,XXY karyotype or somatic mosaicism for the *IKBKG* pathogenic variant.
- An affected male with somatic mosaicism that includes the germline may transmit the *IKBKG* pathogenic variant to female offspring (all daughters inheriting the pathogenic variant would be affected); male offspring are not at risk of inheriting the pathogenic variant.

Other family members

- If a parent of the proband has an *IKBKG* pathogenic variant, the parent's family members may be at risk of being affected.
- X-chromosome inactivation studies to look for evidence of skewing can be helpful in identifying female relatives who have an *IKBKG* pathogenic variant that cannot be identified in the proband.

Related Genetic Counseling Issues

See Management, Evaluation of Relatives at Risk for information on testing at-risk relatives for the purpose of early diagnosis and treatment.

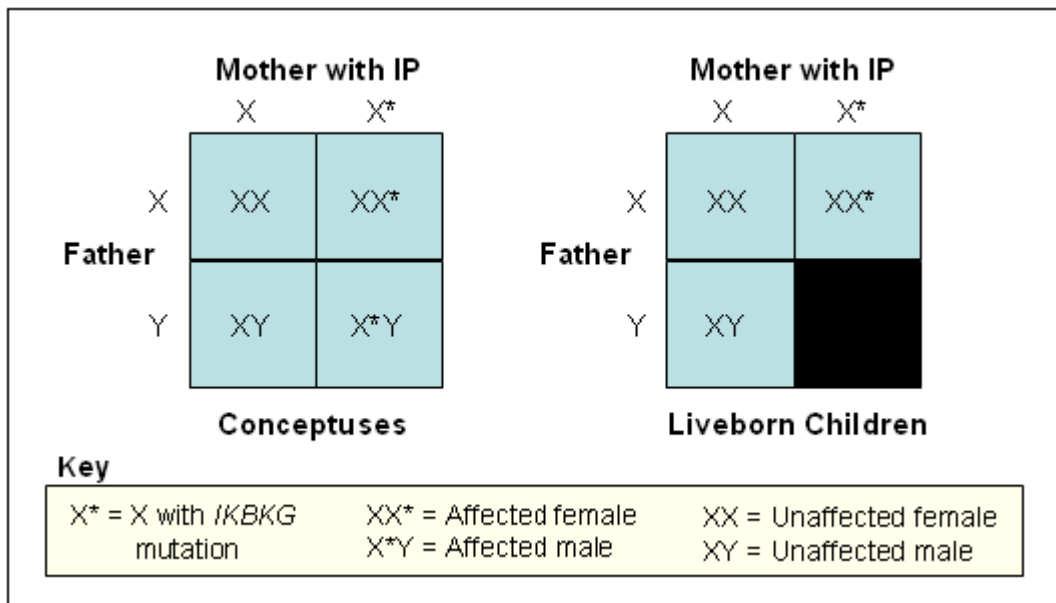


Figure 5. Genotype of conceptuses compared with genotype of live-born children

As with many other genetic conditions, diagnosis of IP in a newborn may result in evaluation and diagnosis of the mother or other family members who were previously unaware of the presence of a genetic disorder in the family. The diagnosis of IP in a newborn can be difficult for the mother and her relatives because of implications for their health and because of a sense of "responsibility" for illness in their offspring. Efforts should be made to anticipate these issues.

Family planning

- The optimal time for determination of genetic risk and discussion of the availability of prenatal/preimplantation genetic testing is before pregnancy.
- It is appropriate to offer genetic counseling (including discussion of potential risks to offspring and reproductive options) to young adults who are affected, have an *IKBKG* pathogenic variant, or are at risk.

DNA banking. Because it is likely that testing methodology and our understanding of genes, pathogenic mechanisms, and diseases will improve in the future, consideration should be given to banking DNA from probands in whom a molecular diagnosis has not been confirmed (i.e., the causative pathogenic mechanism is unknown). For more information, see Huang et al [2022].

Prenatal Testing and Preimplantation Genetic Testing

Once the *IKBKG* pathogenic variant has been identified in an affected family member, prenatal testing and preimplantation genetic testing are possible.

Because the prognosis for affected females differs from that for affected males, the fetal karyotype must be determined for accurate genetic counseling.

- If the fetal karyotype is 46,XX, parents should be informed that 50% of fetuses are likely to be affected with IP.
- If the fetal karyotype is 46,XY, counseling should include discussion of the increased risk of miscarriage of affected males after the first trimester.
- If the fetal karyotype is 47,XXY, counseling should include a discussion of the more severe IP phenotype in males and a discussion of Klinefelter syndrome.

Note: A group of pathogenic variants (mostly in exon 10) that result in a milder IP phenotype in females are associated with a lower risk for miscarriage (see Genotype-Phenotype Correlations).

Resources

GeneReviews staff has selected the following disease-specific and/or umbrella support organizations and/or registries for the benefit of individuals with this disorder and their families. GeneReviews is not responsible for the information provided by other organizations. For information on selection criteria, click [here](#).

- Incontinentia Pigmenti ASSociazione Italiana (I.P.ASS.I.) – Onlus**
 Via Altair, 5
 00012 Guidonia Montecelio
 Italy
Phone: 393332089513
Email: presidenza@incontinentiapigmenti.it
www.incontinentiapigmenti.it
- Incontinentia Pigmenti International Foundation (IPIF)**
 30 East 72nd Street
 New York NY 10021
Phone: 212-452-1231
Fax: 212-452-1406
Email: ipif@ipif.org
www.ipif.org
- National Institute of Neurological Disorders and Stroke (NINDS)**
 PO Box 5801
 Bethesda MD 20824
Phone: 800-352-9424 (toll-free); 301-496-5751; 301-468-5981 (TTY)
[Incontinentia Pigmenti Information Page](#)
- National Library of Medicine Genetics Home Reference**
[Incontinentia pigmenti](#)
- Incontinentia Pigmenti Genetic Biobank (IPGB)**
 IGB-CNR
 Via P. Castellino, 111
 Naples 80131
 Italy
Phone: +39 0816132302
Fax: +39 0816132706
Email: incontinentia.pigmenti@igb.cnr.it
www.igb.cnr.it/ipgb

Molecular Genetics

Information in the Molecular Genetics and OMIM tables may differ from that elsewhere in the GeneReview: tables may contain more recent information. —ED.

Table A. Incontinentia Pigmenti: Genes and Databases

Gene	Chromosome Locus	Protein	Locus-Specific Databases	HGMD	ClinVar
------	------------------	---------	--------------------------	------	---------

Table A. continued from previous page.

<i>IKBKG</i>	Xq28	NF-kappa-B essential modulator	<i>IKBKG</i> @ LOVD IKBKGbase: Mutation registry for Nemo deficiency	<i>IKBKG</i>	<i>IKBKG</i>
--------------	------	--------------------------------	---	--------------	--------------

Data are compiled from the following standard references: gene from [HGNC](#); chromosome locus from [OMIM](#); protein from [UniProt](#). For a description of databases (Locus Specific, HGMD, ClinVar) to which links are provided, click [here](#).

Table B. OMIM Entries for Incontinentia Pigmenti (View All in OMIM)

300248	INHIBITOR OF NUCLEAR FACTOR KAPPA-B KINASE, REGULATORY SUBUNIT GAMMA; <i>IKBKG</i>
308300	INCONTINENTIA PIGMENTI; IP

Molecular Pathogenesis

The genomic organization around *IKBKG* is complex. Within *IKBKG* (previously known as *NEMO*) are two 870-bp direct repeats termed MER67B; one is in intron 3 and the second is downstream of *IKBKG* (Figure 6). Recombination between the MER67B direct repeats results in deletion of exons 4 through 10 of *IKBKG* (previously known as *IKBKGP1*), the common 11.7-kb deletion (Table 2). Rearrangements between other complex repeated elements in the region account for benign variants, which are recurrent among the control population (1%-2% estimated frequency) (Figure 6).

Gene structure. *IKBKG* has multiple transcript variants encoding different isoforms. The transcript variant [NM_003639.3](#) has ten exons. For a detailed summary of gene and protein information, see Table A.

Gene. *IKBKG* has a highly similar pseudogene, designated *IKBKGP1* (also known as *NEMOP*) (Figure 6), located in an adjacent region of the X chromosome. *IKBKGP1* is a partial pseudogene with sequences highly similar to those in exons 3-10 of *IKBKG*.

IKBKG is 22 kb distant from *IKBKGP1*; they are arranged in an inverted fashion.

Benign variants. 10%-12% of parents of individuals with IP were found to have two benign variants:

- A 11.7-kb deletion of exons 4-10 in *IKBKGP1* (Figure 6, upper green chromosome schematic)
- A duplication of MER67B (lower green chromosome schematic) that replicates the exon 4-10 region downstream of the normal *IKBKG* gene (termed MER67Bdup)

Both variants were rare normal variants in a control population [Fusco et al 2009]. These data suggest that the IP locus undergoes recombination producing recurrent variants that could be "at risk" of generating *de novo* in offspring the 11.7-kb pathogenic deletion.

Pathogenic variants. The recurrent pathogenic variant in individuals with IP is an 11.7-kb deletion of exons 4 through 10 of *IKBKG* (Figure 6, red chromosome schematic) (see Molecular Pathogenesis). Figure 6 also depicts some of the non-recurrent deletions that cause IP.

Small intragenic substitutions, deletions, and duplications are scattered throughout *IKBKG*; however, there is a cluster of recurrent pathogenic variants in exon 10, which is extremely GC rich [Fusco et al 2008]. Exon 10 intragenic deletions and duplications that involve the mononucleotide tract of seven cytosines have also been reported [Aradhya et al 2001a, Fusco et al 2008].

Smaller pathogenic variants in *IKBKG* (mostly in exon 10) that result in protein with reduced but not absent activity have been reported [Zonana et al 2000, Aradhya et al 2001a, Döffinger et al 2001, Fusco et al 2008]. These pathogenic variants lead to milder disease in females and support survival of males who have

hypohidrotic ectodermal dysplasia and immunodeficiency (HED-ID) and anhidrotic ectodermal dysplasia with immunodeficiency, osteopetrosis, and lymphedema (OLEDAID) (see Genotype-Phenotype Correlations). For more information, see Table A.

Table 2. Selected *IKBKG* Pathogenic Variants

DNA Nucleotide Change	Predicted Protein Change	Reference Sequences
c.399-?_1260+?del (common 11.7-kb deletion)		NG_009896.1
c.1167dupC	p.Glu390ArgfsTer5	NM_003639.3 NP_003630.1

Variants listed in the table have been provided by the authors. *GeneReviews* staff have not independently verified the classification of variants.

GeneReviews follows the standard naming conventions of the Human Genome Variation Society (varnomen.hgvs.org). See [Quick Reference](#) for an explanation of nomenclature.

Normal gene product. The 2.8-kb *IKBKG* cDNA encodes a 419-amino acid protein, IKK-gamma (nuclear factor-kappaB essential modulator protein; NP_003630.1), which is acidic and rich in glutamic acid and glutamine residues (each 13%) and contains a leucine zipper motif at amino acids 315-342 [Yamaoka et al 1998]. The IKK proteins – alpha, beta, and gamma – form a complex [Rothwarf et al 1998, Li et al 1999, Hayden & Ghosh 2008].

IKK-gamma is produced beginning in early embryogenesis and is expressed ubiquitously [Aradhya et al 2001b]. The normal product, in complex, activates NF-kappaB, which protects against the apoptosis induced by tumor necrosis factor alpha, among many other functions.

Abnormal gene product. Because abnormal or absent IKK-gamma results in the inability to form the normal IKK complex, cells from individuals with IP lack normal NF-kappaB activation. Activated NF-kappaB protects against apoptosis; thus, IP cells are highly sensitive to proapoptotic signals and die easily [Smahi et al 2000].

The 11.7-kb deletion results in a lack of NF-kappaB activation and extreme susceptibility to apoptosis, thus explaining the embryonic death in males and extremely skewed X-chromosome inactivation in females with IP [Smahi et al 2000, Courtois & Smahi 2006]. Two *IKBKG* pathogenic variants associated with severe IP studied at molecular levels showed that impaired NF-kappaB activation in response to diverse external stimuli is the cause of the disease [Sebban-Benin et al 2007, Gautheron et al 2010].

Chapter Notes

Author History

David L Nelson, PhD; Baylor College of Medicine (1996-2010)

Angela Scheuerle, MD, FAAP, FACMG (1996-present)

Matilde Valeria Ursini, PhD (2010-present)

Acknowledgments

Dr Scheuerle's research included above was done at Baylor College of Medicine in the laboratory of Dr David Nelson.

Dr Ursini's work was supported by the Incontinentia Pigmenti International Foundation (IPIF), the Incontinentia Pigmenti France association (IPF), and the Italian Association of Incontinentia Pigmenti (IPASSI).

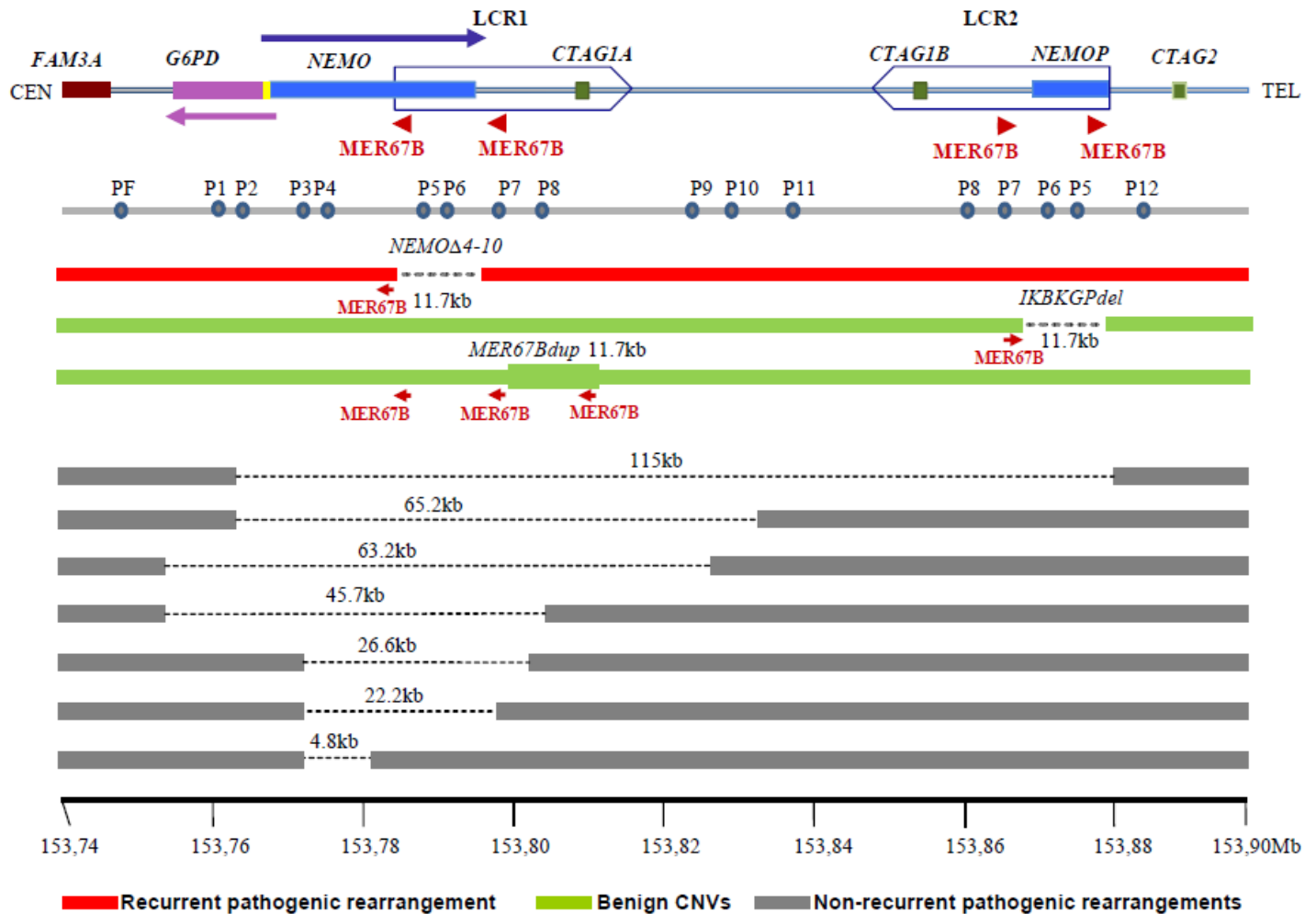


Figure 6. Recurrent and non-recurrent rearrangements in IP locus. The inverted repeats are depicted on the top line by the two large regions outlined by inverted boxes and containing both *MER67B* repeats (red arrows). The location of real-time PCR amplicons assayed to delineate the deletions are labeled PF, P1, P2, etc. See text and Fusco et al [2012] for details. Note: *IKBKGP* was previously known as *NEMO*; *IKBKGP1* was previously known as *NEMOP*.

Revision History

- 21 December 2017 (sw) Comprehensive update posted live
- 12 February 2015 (me) Comprehensive update posted live
- 28 October 2010 (me) Comprehensive update posted live
- 28 January 2008 (cd/as) Revision: Risk to Family Members, Parents of a proband
- 4 October 2007 (me) Comprehensive update posted live
- 31 March 2005 (me) Comprehensive update posted live
- 27 March 2003 (me) Comprehensive update posted live
- 19 December 2000 (me) Comprehensive update posted live
- 8 June 1999 (pb) Review posted live
- 22 December 1998 (as) Original submission

References

Literature Cited

- Alshenqiti A, Nashabat M, AlGhoraibi H, Tamimi O, Alfadhel M. Pulmonary hypertension and vasculopathy in incontinentia pigmenti: a case report. *Ther Clin Risk Manag*. 2017;13:629–634. PubMed PMID: 28533687.
- Aradhya S, Courtois G, Rajkovic A, Lewis RA, Levy M, Israel A, Nelson DL. Atypical forms of incontinentia pigmenti in male individuals result from mutations of a cytosine tract in exon 10 of NEMO (IKK-gamma). *Am J Hum Genet*. 2001a;68:765–71. PubMed PMID: 11179023.
- Aradhya S, Woffendin H, Jakins T, Bardaro T, Esposito T, Smahi A, Shaw C, Levy M, Munnich A, D'Urso M, Lewis RA, Kenwrick S, Nelson DL. A recurrent deletion in the ubiquitously expressed NEMO (IKK-gamma) gene accounts for the vast majority of incontinentia pigmenti mutations. *Hum Mol Genet*. 2001b;10:2171–9. PubMed PMID: 11590134.
- Chang TT, Behshad R, Brodell RT, Gilliam AC. A male infant with anhidrotic ectodermal dysplasia/immunodeficiency accompanied by incontinentia pigmenti and a mutation in the NEMO pathway. *J Am Acad Dermatol*. 2008;58:316–20. PubMed PMID: 18222329.
- Conte MI, Pescatore A, Paciolla M, Esposito E, Miano MG, Lioi MB, McAleer MA, Giardino G, Pignata C, Irvine AD, Scheuerle AE, Royer G, Hadj-Rabia S, Bodemer C, Bonnefont JP, Munnich A, Smahi A, Steffann J, Fusco F, Ursini MV. Insight into IKBKG/NEMO locus: report of new mutations and complex genomic rearrangements leading to incontinentia pigmenti disease. *Hum Mutat*. 2014;35:165–77. PubMed PMID: 24339369.
- Courtois G, Smahi A. NF-kappaB-related genetic diseases. *Cell Death Differ*. 2006;13:843–51. PubMed PMID: 16397577.
- Darné S, Carmichael AJ. Isolated recurrence of vesicobullous incontinentia pigmenti in a schoolgirl. *Br J Dermatol*. 2007;156:600–2. PubMed PMID: 17300267.
- Demirel N, Aydin M, Zenciroglu A, Okumus N, Tekgunduz KS, Ipek MS, Boduroglu E. Incontinentia pigmenti with encephalocele in a neonate: a rare association. *J Child Neurol*. 2009;24:495–9. PubMed PMID: 19339289.
- Döffinger R, Smahi A, Bessia C, Geissmann F, Feinberg J, Durandy A, Bodemer C, Kenwrick S, Dupuis-Girod S, Blanche S, Wood P, Rabia SH, Headon DJ, Overbeek PA, Le Deist F, Holland SM, Belani K, Kumararatne DS, Fischer A, Shapiro R, Conley ME, Reimund E, Kalfhoff H, Abinun M, Munnich A, Israel A, Courtois G, Casanova JL. X-linked anhidrotic ectodermal dysplasia with immunodeficiency is caused by impaired NF-kappaB signaling. *Nat Genet*. 2001;27:277–85. PubMed PMID: 11242109.
- Fiorillo L, Sinclair DB, O'Byrne ML, Krol AL. Bilateral cerebrovascular accidents in incontinentia pigmenti. *Pediatr Neurol*. 2003;29:66–8. PubMed PMID: 13679126.
- Franco LM, Goldstein J, Prose NS, Selim MA, Tirado CA, Coale MM, McDonald MT. Incontinentia pigmenti in a boy with XXY mosaicism detected by fluorescence in situ hybridization. *J Am Acad Dermatol*. 2006;55:136–8. PubMed PMID: 16781308.
- Fusco F, Bardaro T, Fimiani G, Mercadante V, Miano MG, Falco G, Israël A, Courtois G, D'Urso M, Ursini MV. Molecular analysis of the genetic defect in a large cohort of IP patients and identification of novel NEMO mutations interfering with NF-kappaB activation. *Hum Mol Genet*. 2004;13:1763–73. PubMed PMID: 15229184.
- Fusco F, Conte MI, Diociaiuti A, Bigoni S, Branda MF, Ferlini A, El Hachem M, Ursini MV. Unusual father-to-daughter transmission of incontinentia pigmenti due to mosaicism in IP males. *Pediatrics*. 2017;140(3)

- Fusco F, Fimiani G, Tadini G, Michele D, Ursini MV. Clinical diagnosis of incontinentia pigmenti in a cohort of male patients. *J Am Acad Dermatol.* 2007;56:264–7. PubMed PMID: 17224368.
- Fusco F, Paciolla M, Conte MI, Pescatore A, Esposito E, Mirabelli P, Lioi MB, Ursini MV. Incontinentia pigmenti: report on data from 2000 to 2013. *Orphanet J Rare Dis.* 2014;9:93. PubMed PMID: 24961275.
- Fusco F, Paciolla M, Napolitano F, Pescatore A, D'Addario I, Bal E, Lioi MB, Smahi A, Miano MG, Ursini MV. Genomic architecture at the incontinentia pigmenti locus favours de novo pathological alleles through different mechanisms. *Hum Mol Genet.* 2012;21:1260–71. PubMed PMID: 22121116.
- Fusco F, Paciolla M, Pescatore A, Lioi MB, Ayuso C, Faravelli F, Gentile M, Zollino M, D'Urso M, Miano MG, Ursini MV. Microdeletion/duplication at the Xq28 IP locus causes a de novo IKBKG/NEMO/IKKgamma exon4_10 deletion in families with incontinentia pigmenti. *Hum Mutat.* 2009;30:1284–91. PubMed PMID: 19603533.
- Fusco F, Pescatore A, Bal E, Ghoual A, Paciolla M, Lioi MB, D'Urso M, Rabia SH, Bodemer C, Bonnefont JP, Munnich A, Miano MG, Smahi A, Ursini MV. Alterations of the IKBKG locus and diseases: an update and a report of 13 novel mutations. *Hum Mutat.* 2008;29:595–604. PubMed PMID: 18350553.
- Gautheron J, Pescatore A, Fusco F, Esposito E, Yamaoka S, Agou F, Ursini MV, Courtois G. Identification of a new NEMO/TRAF6 interface affected in incontinentia pigmenti pathology. *Hum Mol Genet.* 2010;19:3138–49. PubMed PMID: 20529958.
- Godambe S, McNamara P, Rajguru M, Hellmann J. Unusual neonatal presentation of incontinentia pigmenti with persistent pulmonary hypertension of the newborn: a case report. *J Perinatol.* 2005;25:289–92. PubMed PMID: 15789024.
- Happle R. Incontinentia pigmenti versus hypomelanosis of Ito: the whys and wherefores of a confusing issue. *Am J Med Genet.* 1998;79:64–5. [letter; comment]. PubMed PMID: 9738871.
- Hatchwell E. Unstable mutation in incontinentia pigmenti? *J Med Genet.* 1996;33:349–50. [letter; comment].
- Hayden MS, Ghosh S. Shared principles in NF-kappaB signaling. *Cell.* 2008;132:344–362. PubMed PMID: 18267068.
- Hayes IM, Varigos G, Upjohn EJ, Orchard DC, Penny DJ, Savarirayan R. Unilateral acheiria and fatal primary pulmonary hypertension in a girl with incontinentia pigmenti. *Am J Med Genet A.* 2005;135:302–3. PubMed PMID: 15884011.
- Hennel SJ, Ekert PG, Volpe JJ, Inder TE. Insights into the pathogenesis of cerebral lesions in incontinentia pigmenti. *Pediatr Neurol.* 2003;29:148–50. PubMed PMID: 14580659.
- Huang SJ, Amendola LM, Sternen DL. Variation among DNA banking consent forms: points for clinicians to bank on. *J Community Genet.* 2022;13:389–97. PubMed PMID: 35834113.
- Kenwrick S, Woffendin H, Jakins T, Shuttleworth SG, Mayer E, Greenhalgh L, Whittaker J, Rugolotto S, Bardaro T, Esposito T, D'Urso M, Soli F, Turco A, Smahi A, Hamel-Teillac D, Lyonnet S, Bonnefont JP, Munnich A, Aradhya S, Kashork CD, Shaffer LG, Nelson DL, Levy M, Lewis RA, International IP. Consortium. Survival of male patients with incontinentia pigmenti carrying a lethal mutation can be explained by somatic mosaicism or Klinefelter syndrome. *Am J Hum Genet.* 2001;69:1210–7. PubMed PMID: 11673821.
- Li Y, Kang J, Friedman J, Tarassishin L, Ye J, Kovalenko A, Wallach D, Horwitz MS. Identification of a cell protein (FIP-3) as a modulator of NF-kappaB activity and as a target of an adenovirus inhibitor of tumor necrosis factor alpha-induced apoptosis. *Proc Natl Acad Sci U S A.* 1999;96:1042–7. PubMed PMID: 9927690.
- Mangano S, Barbagallo A. Incontinentia pigmenti: clinical and neuroradiologic features. *Brain Dev.* 1993;15:362–6. PubMed PMID: 8279651.
- Meuwissen ME, Mancini GM. Neurological findings in incontinentia pigmenti; a review. *Eur J Med Genet.* 2012;55:323–31. PubMed PMID: 22564885.

- Minić S, Trpinac D, Obradović M. Incontinentia pigmenti diagnostic criteria update. *Clin Genet*. 2014;85:536–42. PubMed PMID: 23802866.
- Orphanet Report Series. Prevalence and incidence of rare diseases: bibliographic data. *Rare Diseases Collection*. 2017;1:1-73. Available [online](#). Accessed 4-4-22.
- Pacheco TR, Levy M, Collyer JC, de Parra NP, Parra CA, Garay M, Aprea G, Moreno S, Mancini AJ, Paller AS. Incontinentia pigmenti in male patients. *J Am Acad Dermatol*. 2006;55:251–5. PubMed PMID: 16844507.
- Phan TA, Wargon O, Turner AM. Incontinentia pigmenti case series: clinical spectrum of incontinentia pigmenti in 53 female patients and their relatives. *Clin Exp Dermatol*. 2005;30:474–80. PubMed PMID: 16045670.
- Pizzamiglio MR, Piccardi L, Bianchini F, Canzano L, Palermo L, Fusco F, D'Antuono G, Gelmini C, Garavelli L, Ursini MV. Cognitive-behavioural phenotype in a group of girls from 1.2 to 12 years old with incontinentia pigmenti syndrome: recommendations for clinical management. *Appl Neuropsychol Child*. 2017;6:327–34. PubMed PMID: 27267212.
- Pizzamiglio MR, Piccardi L, Bianchini F, Canzano L, Palermo L, Fusco F, D'Antuono G, Gelmini C, Garavelli L, Ursini MV. Incontinentia pigmenti: learning disabilities are a fundamental hallmark of the disease. *PLoS One*. 2014;9:e87771. PubMed PMID: 24489960.
- Richards S, Aziz N, Bale S, Bick D, Das S, Gastier-Foster J, Grody WW, Hegde M, Lyon E, Spector E, Voelkerding K, Rehm HL, et al. Standards and guidelines for the interpretation of sequence variants: a joint consensus recommendation of the American College of Medical Genetics and Genomics and the Association for Molecular Pathology. *Genet Med*. 2015;17:405–24. PubMed PMID: 25741868.
- Rothwarf DM, Zandi E, Natoli G, Karin M. IKK-gamma is an essential regulatory subunit of the IkappaB kinase complex. *Nature*. 1998;395:297–300. PubMed PMID: 9751060.
- Rudolph D, Yeh WC, Wakeham A, Rudolph B, Nallainathan D, Potter J, Elia AJ, Mak TW. Severe liver degeneration and lack of NF-kappaB activation in NEMO/IKKgamma-deficient mice. *Genes Dev*. 2000;14:854–62. PubMed PMID: 10766741.
- Sebban-Benin H, Pescatore A, Fusco F, Pascuale V, Gautheron J, Yamaoka S, Moncla A, Ursini MV, Courtois G. Identification of TRAF6-dependent NEMO polyubiquitination sites through analysis of a new NEMO mutation causing incontinentia pigmenti. *Hum Mol Genet*. 2007;16:2805–15. PubMed PMID: 17728323.
- Shah SN, Gibbs S, Upton CJ, Pickworth FE, Garioch JJ. Incontinentia pigmenti associated with cerebral palsy and cerebral leukomalacia: a case report and literature review. *Pediatr Dermatol*. 2003;20:491–4. PubMed PMID: 14651567.
- Smahi A, Courtois G, Vabres P, Yamaoka S, Heuertz S, Munnich A, Israel A, Heiss NS, Klauck SM, Kioschis P, Wiemann S, Poustka A, Esposito T, Bardaro T, Gianfrancesco F, Ciccodicola A, D'Urso M, Woffendin H, Jakins T, Donnai D, Stewart H, Kenwrick SJ, Aradhya S, Yamagata T, Levy M, Lewis RA, Nelson DL. Genomic rearrangement in NEMO impairs NF-kappaB activation and is a cause of incontinentia pigmenti. The International Incontinentia Pigmenti (IP) Consortium. *Nature*. 2000;405:466–72. PubMed PMID: 10839543.
- Yamaoka S, Courtois G, Bessia C, Whiteside ST, Weil R, Agou F, Kirk HE, Kay RJ, Israel A. Complementation cloning of NEMO, a component of the IkappaB kinase complex essential for NF-kappaB activation. *Cell*. 1998;93:1231–40. PubMed PMID: 9657155.
- Zilberman-Rudenko J, Monaco Shawver L, Wessel AW, Luo Y, Pelletier M, Tsai WL, Lee Y, Vonortas A, Cheng L, Ashwell JD, Orange JS, Siegel RM, Hanson EP. Recruitment of A20 by the C-terminal domain of NEMO suppresses NF- κ B activation and autoinflammatory disease. *Proc Natl Acad Sci USA*. 2016;113:1612–17. PubMed PMID: 26802121.

Zonana J, Elder ME, Schneider LC, Orlow SJ, Moss C, Golabi M, Shapira SK, Farndon PA, Wara DW, Emmal SA, Ferguson BM. A novel X-linked disorder of immune deficiency and hypohidrotic ectodermal dysplasia is allelic to incontinentia pigmenti and due to mutations in IKK-gamma (NEMO). *Am J Hum Genet.* 2000;67:1555–62. PubMed PMID: 11047757.

License

GeneReviews® chapters are owned by the University of Washington. Permission is hereby granted to reproduce, distribute, and translate copies of content materials for noncommercial research purposes only, provided that (i) credit for source (<http://www.genereviews.org/>) and copyright (© 1993-2024 University of Washington) are included with each copy; (ii) a link to the original material is provided whenever the material is published elsewhere on the Web; and (iii) reproducers, distributors, and/or translators comply with the [GeneReviews® Copyright Notice and Usage Disclaimer](#). No further modifications are allowed. For clarity, excerpts of GeneReviews chapters for use in lab reports and clinic notes are a permitted use.

For more information, see the [GeneReviews® Copyright Notice and Usage Disclaimer](#).

For questions regarding permissions or whether a specified use is allowed, contact: admasst@uw.edu.