



Dyskeratosis Congenita and Related Telomere Biology Disorders

Synonym: Zinsser-Cole-Engman Syndrome

Sharon A Savage, MD¹ and Marena R Niewisch, MD^{2,3}

Created: November 12, 2009; Revised: January 19, 2023.

Summary

Clinical characteristics

Dyskeratosis congenita and related telomere biology disorders (DC/TBD) are caused by impaired telomere maintenance resulting in short or very short telomeres. The phenotypic spectrum of telomere biology disorders is broad and includes individuals with classic dyskeratosis congenita (DC) as well as those with very short telomeres and an isolated physical finding. Classic DC is characterized by a triad of dysplastic nails, lacy reticular pigmentation of the upper chest and/or neck, and oral leukoplakia, although this may not be present in all individuals. People with DC/TBD are at increased risk for progressive bone marrow failure (BMF), myelodysplastic syndrome or acute myelogenous leukemia, solid tumors (usually squamous cell carcinoma of the head/neck or anogenital cancer), and pulmonary fibrosis. Other findings can include eye abnormalities (epiphora, blepharitis, sparse eyelashes, ectropion, entropion, trichiasis), taurodontism, liver disease, gastrointestinal telangiectasias, and avascular necrosis of the hips or shoulders. Although most persons with DC/TBD have normal psychomotor development and normal neurologic function, significant developmental delay is present in both forms; additional findings include cerebellar hypoplasia (Hoyeraal Hreidarsson syndrome) and bilateral exudative retinopathy and intracranial calcifications (Revesz syndrome and Coats plus syndrome). Onset and progression of manifestations of DC/TBD vary: at the mild end of the spectrum are those who have only minimal physical findings with normal bone marrow function, and at the severe end are those who have the diagnostic triad and early-onset BMF.

Diagnosis/testing

A majority of individuals with DC/TBD have abnormally short telomeres for their age, as determined by multicolor flow cytometry fluorescence in situ hybridization (flow-FISH) on lymphocyte subsets. To date, *ACD*, *CTC1*, *DKC1*, *NAF1*, *NHP2*, *NOP10*, *PARN*, *POT1*, *RPA1*, *RTEL1*, *STN1*, *TERC*, *TERT*, *TINF2*, *WRAP53*, and

Author Affiliations: 1 Director, Clinical Genetics Branch, Clinical Director, Division of Cancer Epidemiology and Genetics, National Cancer Institute, National Institutes of Health, Bethesda, Maryland; Email: savagesh@mail.nih.gov. 2 Special Volunteer, Clinical Genetics Branch, Division of Cancer Epidemiology and Genetics, National Cancer Institute, National Institutes of Health, Bethesda, Maryland; Email: marena.niewisch@nih.gov. 3 Clinical Fellow, Department of Pediatric Hematology and Oncology, Hannover Medical School, Hannover, Germany; Email: marena.niewisch@nih.gov.

ZCCHC8 are the genes in which pathogenic variants are known to cause DC/TBD and to result in very short telomeres. Pathogenic variants in one of these 16 genes have been identified in approximately 80% of individuals who meet clinical diagnostic criteria for DC/TBD.

Management

Treatment of manifestations: Treatment is tailored to the individual. Hematopoietic cell transplantation (HCT) is the only curative treatment for BMF and leukemia, but long-term outcome has historically been poor due to treatment toxicity; if a suitable donor is not available, androgen therapy may be considered for BMF. Treatment of other cancers is tailored to the type of cancer. Of note, cancer therapy may pose an increased risk for prolonged cytopenias as well as pulmonary and hepatic toxicity. Treatment of pulmonary fibrosis is primarily supportive, although lung transplantation may be considered.

Surveillance: For BMF: complete blood count (CBC) annually if normal and more often if abnormal; annual bone marrow aspirate and biopsy. For those on androgen therapy: routine monitoring of CBC, liver function, liver ultrasound, and endocrinology evaluation. For cancer risk: monthly self-examination for oral, head, and neck cancer; annual cancer screening by an otolaryngologist and dermatologist; annual gynecologic examination. For pulmonary fibrosis: annual pulmonary function tests starting either at diagnosis or when the individual can perform the test (often age ~8 years); bubble echocardiogram to look for pulmonary arteriovenous malformations if suspected based on clinical symptoms. Routine dental screening every six months and good oral hygiene are recommended.

Agents/circumstances to avoid: Blood donation by family members if HCT is being considered; non-leukodepleted and non-irradiated blood products; the combination of androgens and granulocyte colony-stimulating factor in treatment of BMF (has been associated with splenic rupture); toxic agents implicated in tumorigenesis (e.g., smoking, excessive sun exposure).

Evaluation of relatives at risk: If a relative has signs or symptoms suggestive of DC/TBD or is being evaluated as a potential HCT donor, telomere length testing – or, if the pathogenic variant(s) in the family are known, molecular genetic testing – is warranted.

Genetic counseling

The mode of inheritance of DC/TBD varies by gene:

- X-linked: *DKC1*
- Autosomal dominant: *NAF1*, *RPA1*, *TERC*, *TINF2*, and *ZCCHC8*
- Autosomal dominant or autosomal recessive: *ACD*, *PARN*, *RTEL1*, and *TERT*
- Autosomal recessive: *CTC1*, *NHP2*, *NOP10*, *POT1*, *STN1*, and *WRAP53*

Genetic counseling regarding risk to family members depends on accurate diagnosis, determination of the mode of inheritance in each family, and results of molecular genetic testing. Once the DC/TBD-related pathogenic variant(s) have been identified in an affected family member, prenatal and preimplantation genetic testing are possible.

GeneReview Scope

Telomere Biology Disorders: Phenotypic Spectrum

- Classic dyskeratosis congenita
- Hoyeraal Hreidarsson syndrome
- Revesz syndrome
- Coats plus syndrome

Diagnosis

Dyskeratosis congenita and related telomere biology disorders (DC/TBD) are caused by impaired telomere maintenance resulting in short or very short telomeres. The phenotypic spectrum of telomere biology disorders is broad and includes individuals with classic dyskeratosis congenita (DC) as well as those with very short telomeres and an isolated physical finding [Savage & Bertuch 2010, Dokal 2011, Ballew & Savage 2013, Bertuch 2016, Niewisch & Savage 2019, Niewisch et al 2022].

The criteria for classic DC were described by Vulliamy et al [2006]; see Suggestive Findings. Note, however, that individuals may develop features of a DC/TBD at variable rates and ages, which can make proper diagnosis challenging.

Suggestive Findings

A telomere biology disorder (TBD), including dyskeratosis congenita (DC), **should be suspected** in individuals with the following clinical findings.

Physical characteristics. One of the following:

- At least two features of the classic DC clinical triad (Figure 1):
 - Dysplastic nails. Findings may be subtle with ridging, flaking, or poor growth, or more diffuse with nearly complete loss of nails.
 - Lacy reticular pigmentation of the upper chest and/or neck. May be subtle or diffuse hyper- or hypopigmentation. Note that abnormal pigmentation changes are not restricted to the upper chest and neck.
 - Oral leukoplakia (white patches in the mouth)
- One feature of the classic triad or suggestive family history (occurrence of bone marrow failure [BMF], myelodysplastic syndrome [MDS], acute myelogenous leukemia [AML], early-onset head/neck squamous cell cancer [HNSCC], and/or pulmonary fibrosis [PF] in a first- or second-degree relative) in combination with:
 - Progressive BMF. May appear at any age and may be a presenting sign. Macrocytosis and elevated hemoglobin F levels may be seen.
 - MDS or AML. May be the presenting sign.
 - Solid tumors, usually HNSCC or anogenital adenocarcinoma, in persons younger than age 50 years and without other risk factors. Solid tumors may be the first manifestation of DC/TBD in individuals who do not have BMF.
 - PF. See [Pulmonary Fibrosis Predisposition Overview](#).
- Any feature of the classic triad plus two or more of the following:
 - Epiphora (excessive watering of the eye[s])
 - Blepharitis (inflammation of the eyelids, often due to epiphora)
 - Abnormal eyelash growth
 - Prematurely gray hair
 - Alopecia
 - Taurodontism (enlarged tooth pulp chambers) or decreased tooth root-to-crown ratio
 - Developmental delay
 - Short stature
 - Microcephaly
 - Hypogonadism

- Esophageal stenosis
- Urethral stenosis
- Liver disease
- Osteoporosis
- Avascular necrosis of the hips or shoulders
- Gastrointestinal telangiectasias
- Pulmonary arteriovenous malformations

Note: Individuals with TBDs may have none of the above additional findings or the findings may appear or worsen with age.

Establishing the Diagnosis

The diagnosis of DC/TBD is **established** in a proband with characteristic clinical findings and either of the following:

- Shortened telomere length as determined by lymphocyte telomere length testing by automated multicolor flow cytometry fluorescence in situ hybridization (flow-FISH) in the six-cell panel assay. Telomere length less than the first centile for age in lymphocytes is 97% sensitive and 91% specific for DC/TBD. In individuals with complex or atypical DC/TBD, the six-cell panel may be more informative than the two-panel test of total lymphocytes and granulocytes [Alter et al 2012].
- Identification of biallelic pathogenic (or likely pathogenic) variants in one of the six genes known to solely cause autosomal recessive DC/TBD; or a heterozygous pathogenic (or likely pathogenic) variant in one of the five genes known to cause autosomal dominant DC/TBD; or a mono- or biallelic pathogenic (or likely pathogenic) variant in one of the four genes associated with autosomal recessive and dominant DC/TBD; or a hemizygous pathogenic (or likely pathogenic) variant in *DKC1* known to cause X-linked DC/TBD (see Table 1).

Note: (1) Per ACMG/AMP variant interpretation guidelines, the terms "pathogenic variants" and "likely pathogenic variants" are synonymous in a clinical setting, meaning that both are considered diagnostic and both can be used for clinical decision making [Richards et al 2015]. Reference to "pathogenic variants" in this section is understood to include any likely pathogenic variants. (2) The identification of variant(s) of uncertain significance cannot be used to confirm or rule out the diagnosis.

Molecular genetic testing approaches can include a combination of **gene-targeted testing** (multigene panel) and **comprehensive genomic testing** (exome sequencing, genome sequencing) depending on the phenotype.

Gene-targeted testing requires that the clinician determine which gene(s) are likely involved, whereas genomic testing does not. Individuals with the distinctive findings described in Suggestive Findings are likely to be diagnosed using gene-targeted testing (see Option 1), whereas those in whom the diagnosis of DC/TBD has not been considered are more likely to be diagnosed using genomic testing (see Option 2).

Option 1

A **multigene panel** that includes the genes listed in Table 1 and other genes of interest (see Differential Diagnosis) is most likely to identify the genetic cause of the condition while limiting identification of variants of uncertain significance and pathogenic variants in genes that do not explain the underlying phenotype. Note: (1) The genes included in the panel and the diagnostic sensitivity of the testing used for each gene vary by laboratory and are likely to change over time. (2) Some multigene panels may include genes not associated with the condition discussed in this *GeneReview*. (3) In some laboratories, panel options may include a custom laboratory-designed panel and/or custom phenotype-focused exome analysis that includes genes specified by the clinician. (4) Methods used in a panel may include sequence analysis, deletion/duplication analysis, and/or other non-sequencing-based tests.

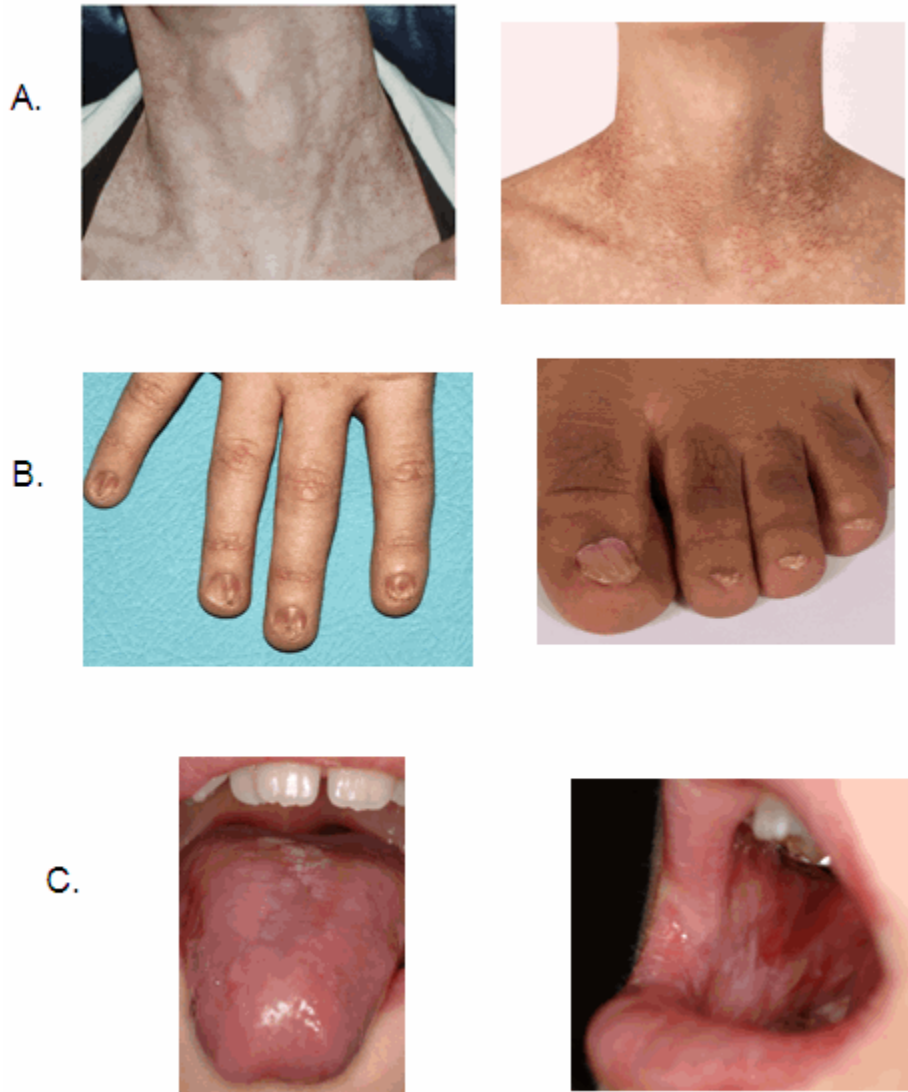


Figure 1. Examples of the dyskeratosis congenita diagnostic triad

- A. Skin pigmentation
- B. Dysplastic fingernails and toenails
- C. Oral leukoplakia

For an introduction to multigene panels click [here](#). More detailed information for clinicians ordering genetic tests can be found [here](#).

Option 2

Comprehensive genomic testing does not require the clinician to determine which gene is likely involved. **Exome sequencing** is most commonly used; **genome sequencing** is also possible.

For an introduction to comprehensive genomic testing click [here](#). More detailed information for clinicians ordering genomic testing can be found [here](#).

Table 1. Molecular Genetic Testing Used in Dyskeratosis Congenita and Related Telomere Biology Disorders (DC/TBD)

Gene ^{1, 2}	MOI	Proportion of DC/TBD Attributed to Pathogenic Variants in Gene ³	Proportion of Probands with Pathogenic Variants ⁴ Detected by Method	
			Sequence analysis ⁵	Gene-targeted deletion/duplication analysis ⁶
<i>ACD</i>	AD or AR	<1%	2/2 families ⁷	Unknown ⁸
<i>CTC1</i>	AR	1%-3%	~100% ⁹	
<i>DKC1</i>	XL	20%-25%	~100% ⁷	
<i>NAF1</i>	AD	<1%	2/2 families ¹⁰	
<i>NHP2</i>	AR	<1%	6/6 families ¹¹	
<i>NOPI0</i>	AR	<1%	2/2 families ¹²	
<i>PARN</i>	AR or AD	<1%	9/9 families ¹³	
<i>POT1</i>	AR ¹⁴	<1%	1/1 family ¹⁵	
<i>RPA1</i>	AD	<1%	4/4 families ¹⁶	
<i>RTEL1</i>	AD or AR	2%-8%	~100% ⁷	
<i>STN1</i>	AR	<1%	2/2 families ¹⁷	
<i>TERC</i>	AD	5%-10%	~100% ⁷	
<i>TERT</i>	AD or AR	1%-7%	~100% ⁷	
<i>TINF2</i>	AD	12%-20%	~100% ⁷	
<i>WRAP53</i>	AR	<1%	5/5 families ¹⁸	
<i>ZCCHC8</i>	AD	<1%	1/1 family ¹⁹	

Table 1. continued from previous page.

Gene ^{1, 2}	MOI	Proportion of DC/TBD Attributed to Pathogenic Variants in Gene ³	Proportion of Proband with Pathogenic Variants ⁴ Detected by Method	
			Sequence analysis ⁵	Gene-targeted deletion/duplication analysis ⁶
Unknown ²⁰		20%	NA	

AD = autosomal dominant; AR = autosomal recessive; MOI = mode of inheritance; NA = not applicable; XL = X-linked

1. Genes are listed in alphabetic order.

2. See Table A. Genes and Databases for chromosome locus and protein.

3. Data from Ballew & Savage [2013]; Dokal et al [2015]; Glousker et al [2015]; Bertuch [2016]; Author, personal observation

4. See Molecular Genetics for information on variants detected in these genes.

5. Sequence analysis detects variants that are benign, likely benign, of uncertain significance, likely pathogenic, or pathogenic. Variants may include small intragenic deletions/insertions and missense, nonsense, and splice site variants; typically, exon or whole-gene deletions/duplications are not detected. For issues to consider in interpretation of sequence analysis results, click [here](#).

6. Gene-targeted deletion/duplication analysis detects intragenic deletions or duplications. Methods used may include a range of techniques such as quantitative PCR, long-range PCR, multiplex ligation-dependent probe amplification (MLPA), and a gene-targeted microarray designed to detect single-exon deletions or duplications.

7. Guo et al [2014], Kocak et al [2014]

8. No data on detection rate of gene-targeted deletion/duplication analysis are available for the listed genes.

9. Data derived from the subscription-based professional view of Human Gene Mutation Database [Stenson et al 2020]

10. Stanley et al [2016]

11. Vulliamy et al [2008], Benyelles et al [2020]

12. Walne et al [2007], Balogh et al [2020]

13. Tummala et al [2015], Moon et al [2015], Burris et al [2016], Dodson et al [2019], Zeng et al [2020], Belaya et al [2021]

14. For heterozygous pathogenic variants, see Genetically Related Disorders.

15. Takai et al [2016]

16. Sharma et al [2022]

17. Simon et al [2016]

18. Zhong et al [2011], Shao et al [2018], Bergstrand et al [2020], Brailovski et al [2022]

19. Gable et al [2019]

20. Approximately 80% of individuals who meet clinical diagnostic criteria for DC/TBD have a pathogenic variant(s) in one of the 15 known DC/TBD-related genes.

Tissue-restricted mosaicism has been observed in a limited number of individuals with DC/TBD. A *TERC* germline pathogenic variant that was not observed by molecular genetic testing of DNA extracted from peripheral blood cells was detected in DNA extracted from other cells (e.g., skin fibroblasts) of the individual [Jongmans et al 2012]. Similarly, hematopoietic somatic reversion was also reported in an individual with a germline *RPA1* variant Sharma et al [2022]. The assumption is that the selective advantage of the revertant hematopoietic cells allows them to populate the bone marrow, resulting in the inability to detect the pathogenic variant in DNA extracted from these cells. Molecular genetic testing of a second tissue source may be considered in individuals who meet the diagnostic criteria for DC/TBD but do not have a pathogenic variant identified on molecular genetic testing of peripheral blood cells.

Clinical Characteristics

Clinical Description

The classic dyskeratosis congenita (DC) triad of abnormal fingernails and toenails, lacy, reticular pigmentation of the neck and upper chest, and oral leukoplakia is diagnostic (Figure 1); however, these features are not present in all individuals with DC and related telomere biology disorders (DC/TBD) and may or may not develop over time after the appearance of other complications listed here [Savage & Bertuch 2010, Dokal 2011, Ward et al 2018, Niewisch et al 2022]. The time of onset for these medical complications varies considerably among

individuals even within the same family and thus the manifestations of DC/TBD do not progress in a predictable pattern. The spectrum ranges from individuals who develop bone marrow failure (BMF) first and then years later develop other classic findings such as nail abnormalities, to others who have severe nail problems and abnormalities of skin pigmentation but normal bone marrow function.

Three forms of DC/TBD with more severe manifestations have been identified: **Hoyeraal Hreidarsson syndrome**, **Revesz syndrome**, and **Coats plus syndrome** (see Severe Forms of DC/TBD).

Table 2. Dyskeratosis Congenita and Related Telomere Biology Disorders (DC/TBD): Frequency of Select Features

Feature	Frequency ¹			Comment
	In nearly all	Common	Infrequent	
Lacy reticular pigmentation ²		●		Predominantly located on neck; may develop over time
Dysplastic nails ²	●			May develop over time
Oral leukoplakia ²		●		May be present intermittently & may progress to malignant lesions
Epiphora ²		●		
Taurodontism		●		
Short stature			●	
Developmental delay ³		●		Predominantly in Hoyeraal Hreidarsson syndrome, Revesz syndrome, & Coats plus syndrome
Microcephaly		●		Most common in Hoyeraal Hreidarsson syndrome & Revesz syndrome
Hypogonadism			●	
Esophageal stenosis		●		
Liver disease ⁴		●		May be more common after HCT
Gastrointestinal telangiectasias ⁵		●		May be more common after HCT
Urethral stenosis			●	Predominantly described in males
Osteoporosis			●	
Avascular necrosis of hips or shoulders		●		
Cardiovascular concerns			●	Rarely occurs, not a typical finding in DC/TBD
Bone marrow failure		●		May be presenting concern
Myelodysplastic syndrome or leukemia ⁶		●		
Head/neck squamous cell cancer		●		Head/neck cancers occurring in young persons (age <40 yrs) warrant consideration of DC/TBD.
Pulmonary fibrosis ⁷		●		May be more common after HCT
Pulmonary arteriovenous malformations ⁸		●		May be more common after HCT

Table 2. continued from previous page.

Feature	Frequency ¹			Comment
	In nearly all	Common	Infrequent	
Immunologic abnormalities		●		

HCT = hematopoietic cell transplant

1. Most frequencies based on Niewisch et al [2022]; additional data indicated by footnote citations

2. Ward et al [2018]

3. Bhala et al [2019]

4. Kapuria et al [2019]

5. Higgs et al [2019]

6. Alter et al [2018]

7. Giri et al [2019]

8. Khincha et al [2017]

Dermatologic. Lacy, reticular pigmentation primarily of the neck and chest may be subtle or diffuse hyper- or hypopigmentation. Changes in skin pigmentation may not be present at time of diagnosis, but may develop or become more pronounced over time.

Dysplastic fingernails and toenails may worsen significantly over time and nails may eventually "disappear."

Additional common skin findings in DC/TBD include epiphora, loss of dermatoglyphics, early graying, palmoplantar hyperkeratosis, eyelash loss, and hair loss from scalp [Ward et al 2018]. Dermatoglyphics may be lost with age.

Hyperhidrosis is noted infrequently in some individuals.

Ears, nose, and throat. Oral leukoplakia is part of the diagnostic triad. It may be a presenting sign found in childhood or may develop over time.

Deafness has been reported but is rare.

Ophthalmic. Epiphora caused by stenosis of the lacrimal drainage system can result in blepharitis.

Abnormal eyelash growth includes sparse eyelashes, ectropion, entropion, and trichiasis, which can lead to corneal abrasions, scarring, or infection if not treated.

Bilateral exudative retinopathy seen in Revesz syndrome or Coats plus syndrome can lead to blindness.

Dental. Decreased root-to-crown ratio is attributed to abnormal tooth development.

Taurodontism (enlarged pulp chambers of the teeth) may be noted on dental x-ray.

Growth and development. Short stature has been reported but height is variable.

Intrauterine growth restriction (IUGR) has been noted in children with the more severe Coats plus syndrome, Hoyeraal Hreidarsson syndrome, or Revesz syndrome.

Developmental delay may be present in some. It can be more pronounced in persons with Hoyeraal Hreidarsson syndrome, Revesz syndrome, or Coats plus syndrome.

Neurologic. Although most persons with DC/TBD have normal psychomotor development and normal neurologic function, significant developmental delay / intellectual disability is present in Hoyeraal Hreidarsson syndrome and Revesz syndrome. Cerebellar hypoplasia is present in Hoyeraal Hreidarsson syndrome (Figure 2), and intracranial calcifications have been reported in Revesz syndrome and Coats plus syndrome. Microcephaly

has also been reported in some persons with DC/TBD, most commonly in Hoyeraal Hreidarsson syndrome and Revesz syndrome.

Psychiatric. Clinically significant psychiatric diagnosis was reported in 27% of 44 individuals with DC/TBD in a recent retrospective study. The psychiatric diagnoses in adults included depression and/or anxiety/panic attacks, autism spectrum disorder, and bipolar disorder [Bhala et al 2019]. However, the true prevalence of psychiatric disorders is unknown.

Endocrine. Hypogonadism has been noted in a small number of severely affected males.

Gastrointestinal. Esophageal stenosis has been reported in several persons with DC/TBD and may worsen over time.

Enteropathy, which may result in poor growth, has been reported, specifically in Hoyeraal Hreidarsson syndrome.

Liver disease, including nodular regenerative hyperplasia, fibrosis, cirrhosis, portal hypertension, and hepatopulmonary syndrome, is increasingly recognized as a potential severe complication of DC/TBD and may lead to liver transplant [Gorgy et al 2015, Kapuria et al 2019, Niewisch et al 2022]. Individuals who have undergone hematopoietic cell transplant (HCT) need close monitoring for liver disease.

Gastrointestinal telangiectasias and bleeding may occur in the context of portal hypertension or independently.

Genitourinary. Urethral stenosis in males may be present at diagnosis or develop over time.

Musculoskeletal. Osteoporosis and osteopenia have been reported. The contribution of prior treatment and comorbid conditions to these complications is not known. Some individuals have reported bone fractures after minor trauma.

Avascular necrosis of the hips and shoulders can result in pain and reduced function. Several individuals have required hip replacement surgery at young ages.

Cardiovascular. Rare reported congenital heart defects include atrial and ventricular septal defects, myocardial fibrosis, and dilated cardiomyopathy.

Hematologic. Bone marrow failure is a common presenting sign, may develop at any age, and may progress over time. Approximately one half of individuals with DC/TBD develop some degree of bone marrow failure by age 40 years.

Individuals with DC/TBD are at increased risk for leukemia (see **Cancer**).

Immunologic. Immunodeficiency of variable severity has been reported in DC/TBD. It has not been fully characterized, but it appears that some individuals may have reduced numbers of B cells, T cells, and/or NK cells.

Cancer. Persons with DC/TBD are at high risk for leukemia and squamous cell cancer of the head and neck or anogenital region. Elevated risk of cervical squamous cell cancer has also been reported in DC/TBD.

Investigators at the National Cancer Institute analyzed data from 15 years of follow up in a longitudinal cohort study to further quantify cancer risk in individuals with DC/TBD (n=197). The median age of onset for all cancers was 38 years (range 18-63 years), with an O/E (observed deaths to expected deaths) ratio of 4.2 compared to the normal population. The most frequent solid tumors were head and neck squamous cell carcinomas (with an O/E ratio of 74), followed by leukemia, non-Hodgkin lymphoma, and anorectal carcinoma. Of note, the risk of tongue cancer was increased by 216-fold over the normal population. In this study,

myelodysplastic syndrome (MDS) was observed at a 578-fold increased risk, and the median age of MDS onset was 31 years (range 4-73 years).

Respiratory. Pulmonary fibrosis may be a presenting sign or may develop over time. It may be more common in individuals who have had HCT. Pulmonary fibrosis is manifest as bibasilar reticular abnormalities, ground glass opacities, or diffuse nodular lesions on high-resolution computed tomography and abnormal pulmonary function studies that include evidence of restriction (reduced vital capacity with an increase in FEV1/FVC ratio) and/or impaired gas exchange (increased $P_{(A-a)}O_2$ with rest or exercise or decreased diffusion capacity of the lung for carbon monoxide).

Pulmonary arteriovenous malformations have recently been reported in individuals with DC/TBD [Khincha et al 2017]. They may be present in individuals with hypoxia in the absence of pulmonary fibrosis and can be diagnosed by bubble echocardiography.

Severe Forms of DC/TBD

Hoyeraal Hreidarsson syndrome, a very severe form of DC/TBD, presents in early childhood [Walne & Dokal 2008]. In addition to features of DC/TBD, cerebellar hypoplasia is required to establish the diagnosis (see Figure 2). The findings in the original cases included cerebellar hypoplasia, developmental delay, immunodeficiency, IUGR, and bone marrow failure, as well as the DC/TBD diagnostic triad [Hoyeraal et al 1970].

Revesz syndrome has many of the features of DC/TBD and presents in early childhood [Revesz et al 1992]. In addition to features of DC/TBD, bilateral exudative retinopathy is required to establish the diagnosis. The individuals in the original reports had intracranial calcifications, IUGR, bone marrow failure, and sparse, fine hair in addition to nail dystrophy and oral leukoplakia.

Coats plus syndrome may include DC/TBD-related mucocutaneous changes, such as dystrophic nails and sparse or graying hair [Anderson et al 2012, Polvi et al 2012]. Additionally, it typically includes bilateral exudative retinopathy, retinal telangiectasias, IUGR, intracranial calcifications, osteopenia with tendency to fracture with poor bone healing, and gastrointestinal vascular ectasias [Linnankivi et al 2006, Briggs et al 2008].

Clinical Findings of X-Linked DC/TBD in Females

Clinical manifestations in females heterozygous for *DKC1* pathogenic variants have been reported, including skin pigmentation abnormalities, nail dysplasia, and bone marrow failure [Vulliamy et al 2006, Xu et al 2016, Hirvonen et al 2019].

Phenotype Correlations by Gene

Classic DC with severe bone marrow failure and mucocutaneous triad features is associated with autosomal recessive, X-linked, or *TINF2*-related autosomal dominant DC/TBD. Significant better overall survival is observed in those with DC/TBD with an underlying autosomal dominant variant (excluding *TINF2*) versus those with DC associated with other types of variants [Niewisch et al 2022].

Individuals with autosomal recessive or X-linked DC/TBD have been reported to show more neurologic findings than those with autosomal dominant DC/TBD [Bhala et al 2019].

Pulmonary fibrosis without prior HCT is more frequently reported in individuals with autosomal dominant forms of DC/TBD [Armanios et al 2007, Giri et al 2019, Niewisch et al 2022].

Genotype-Phenotype Correlations

Due to the rarity of DC/TBD, no specific genotype-phenotype correlations have been identified.

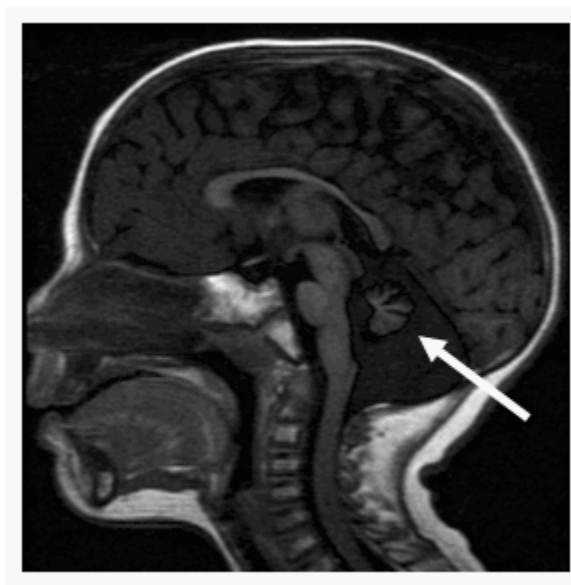


Figure 2. MRI of cerebellar hypoplasia in an individual with Hoyeraal Hreidarsson syndrome. Arrow indicates the hypoplastic cerebellum.

Penetrance

The penetrance of DC/TBD and DC/TBD-associated medical complications is not well understood. Due to the variability between individuals (even within the same family) and the observation that medical complications may increase with age, penetrance may appear incomplete. Recent studies report somatic *TERT* promotor variants as possible modifiers to germline pathogenic variants [Maryoung et al 2017, Gutierrez-Rodriguez et al 2019]. However, additional studies are needed to further understand the components leading to variable penetrance of DC/TBD-causing variants.

Nomenclature

Revesz syndrome [Revesz et al 1992], Hoyeraal Hreidarsson syndrome [Hoyeraal et al 1970, Hreidarsson et al 1988], and Coats plus syndrome [Linnankivi et al 2006, Briggs et al 2008], previously thought to be distinct disorders, are now recognized to be part of the phenotypic spectrum of dyskeratosis congenita.

A few case reports of a syndrome of ataxia and pancytopenia are actually describing DC/TBD caused by pathogenic variants in *TINF2* [Tsangaris et al 2008].

Prevalence

The prevalence of DC/TBD in the general population is not known; DC/TBD is believed to be rare. As of March 2022, the authors are aware of approximately 800-1,000 affected individuals.

Genetically Related (Allelic) Disorders

No phenotypes other than those discussed in this *GeneReview* are known to be associated with germline pathogenic variants in *ACD*, *CTC1*, *DKC1*, *NAF1*, *NHP2*, *NOP10*, *PARN*, *RPA1*, *RTEL1*, *STN1*, *TERC*, *TERT*, *TINF2*, *WRAP53*, or *ZCCHC8*.

Heterozygous germline pathogenic variants in *POT1* are associated with *POT1* tumor predisposition (*POT1*-TDP). *POT1*-TDP is characterized by an increased lifetime risk for multiple cutaneous melanomas, chronic

lymphocytic leukemia, angiosarcoma (particularly cardiac angiosarcomas), and gliomas. The majority of *POT1*-associated cancers are diagnosed in adulthood.

Differential Diagnosis

Disorders with clinical features that overlap those of dyskeratosis congenita and related telomere biology disorders (DC/TBD) are described below.

Disorders with Nail Dysplasia

Table 3. Disorders with Nail Dysplasia in the Differential Diagnosis of Dyskeratosis Congenita and Related Telomere Biology Disorders (DC/TBD)

Gene	Disorder	MOI	Clinical Characteristics	Comment
<i>FZD6</i>	Twenty-nail dystrophy (OMIM 161050)	AR	Onychauxis, hyponychia, & onycholysis	Nonsyndromic nail disorder
<i>LMX1B</i>	Nail-patella syndrome	AD	Classic clinical tetrad of changes in nails, knees, & elbows, & presence of iliac horns	Nails may be absent, hypoplastic, or dystrophic; ridged longitudinally or horizontally; pitted; discolored; separated into 2 halves by longitudinal cleft or ridge of skin; & thin or (less often) thickened.
<i>USB1</i>	Poikiloderma with neutropenia	AR	Post-inflammatory poikiloderma & chronic noncyclic neutropenia typically assoc w/ recurrent sinopulmonary infections & (often) bronchiectasis. ↑ risk for myelodysplastic syndrome. Other findings incl nail dystrophy & palmar/plantar hyperkeratosis.	Thickened, hyperkeratotic toenails are common; dystrophic nails that can slough may also be seen.

AD = autosomal dominant; AR = autosomal recessive; MOI = mode of inheritance

Inherited Bone Marrow Failure Syndromes

Bone marrow failure syndromes are a complex set of related disorders that may have bone marrow failure as the first presenting sign.

Table 4. Inherited Bone Marrow Failure Syndromes in the Differential Diagnosis of Dyskeratosis Congenita and Related Telomere Biology Disorders (DC/TBD)

Gene	Disorder	MOI	Clinical Characteristics	Comment
<i>BRCA1</i> <i>BRCA2</i> <i>BRIP1</i> <i>ERCC4</i> <i>FAAP100</i> <i>FANCA</i> <i>FANCB</i> <i>FANCC</i> <i>FANCD2</i> <i>FANCE</i> <i>FANCF</i> <i>FANCG</i> <i>FANCI</i> <i>FANCL</i> <i>FANCM</i> <i>PALB2</i> <i>RAD51</i>	Fanconi anemia (FA)	AR XL AD ¹	The primary clinical features of FA are physical abnormalities, progressive BMF manifesting as pancytopenia, & cancer susceptibility; however, some persons w/FA have neither physical abnormalities nor BMF.	The 1st clinical manifestation of both FA & DC/TBD may be BMF.

Table 4. continued from previous page.

Gene	Disorder	MOI	Clinical Characteristics	Comment
<i>RAD51C</i> <i>REV7</i> <i>RFWD3</i> <i>SLX4</i> <i>UBE2T</i> <i>XRCC2</i>				
<i>DNAJC21</i> <i>EFL1</i> <i>SBDS</i> <i>SRP54</i>	Shwachman-Diamond syndrome (SDS)	AR AD ²	Exocrine pancreatic dysfunction w/ malabsorption, malnutrition, & growth failure; hematologic abnormalities w/single- or multi-lineage cytopenias & susceptibility to MDS & AML; & bone abnormalities. In almost all affected children, persistent or intermittent neutropenia is a common presenting finding. Short stature & recurrent infections are common.	Like DC/TBD, SDS may 1st present as BMF or GI malabsorption.
<i>GATA1</i> <i>RPL11</i> <i>RPL15</i> <i>RPL18</i> <i>RPL26</i> <i>RPL27</i> <i>RPL31</i> <i>RPL35</i> <i>RPL35A</i> <i>RPL5</i> <i>RPL9</i> <i>RPS10</i> <i>RPS15A</i> <i>RPS17</i> <i>RPS19</i> <i>RPS24</i> <i>RPS26</i> <i>RPS27</i> <i>RPS28</i> <i>RPS29</i> <i>RPS7</i> <i>TSR2</i>	Diamond-Blackfan anemia (DBA)	AD XL ³	In its classic form, profound normochromic & usually macrocytic anemia w/normal leukocytes & platelets, congenital malformations (≤50%), & growth restriction (30%). The hematologic complications occur in 90% of affected persons during 1st yr of life. ↑ risk for AML, MDS, & solid tumors.	DBA & DC/TBD may 1st present w/BMF.

AD = autosomal dominant; AML = acute myelogenous leukemia; AR = autosomal recessive; BMF = bone marrow failure; DC = dyskeratosis congenita; GI = gastrointestinal; MDS = myelodysplasia syndrome; MOI = mode of inheritance; XL = X-linked
1. Fanconi anemia (FA) can be inherited in an autosomal recessive manner, an autosomal dominant manner (*RAD51*-related FA), or an X-linked manner (*FANCB*-related FA).

2. Shwachman-Diamond syndrome (SDS) caused by pathogenic variants in *DNAJC21*, *EFL1*, or *SBDS* is inherited in an autosomal recessive manner. SDS caused by pathogenic variants in *SRP54* is inherited in an autosomal dominant manner.

3. Diamond-Blackfan anemia (DBA) is most often inherited in an autosomal dominant manner; *GATA1*-related and *TSR2*-related DBA are inherited in an X-linked manner.

Acquired Aplastic Anemia

Characterized by tri-lineage bone marrow cytopenias [Young 2018], acquired aplastic anemia is often progressive and may occur at any age. Telomere length testing helps identify the subset of individuals with later-onset aplastic anemia who have a telomere biology disorder; these individuals may have a few or none of the other clinical findings of DC/TBD. Other known causes of aplastic anemia include an immune process, infection, or drug reaction. In many individuals the cause of acquired aplastic anemia is unknown.

Idiopathic Pulmonary Fibrosis

Idiopathic pulmonary fibrosis (IPF) is the most frequent idiopathic interstitial pneumonia. It results in progressive fibrotic lung disease and has high morbidity and mortality. Persons with DC/TBD may develop IPF and it is conceivable that IPF in a young person could be the first manifestation of DC/TBD; thus, DC/TBD should be considered in young persons with IPF. See [Pulmonary Fibrosis Predisposition Overview](#).

Management

Evaluations Following Initial Diagnosis

To establish the extent of disease and needs in an individual diagnosed with dyskeratosis congenita (DC) or a related telomere biology disorder (TBD), it is important to note that the clinical spectrum of DC/TCB is broad and signs and symptoms develop at various ages and rates. The evaluations summarized in Table 5 (if not performed as part of the evaluation that led to the diagnosis) are recommended.

Table 5. Recommended Evaluations Following Initial Diagnosis in Individuals with Dyskeratosis Congenita and Related Telomere Biology Disorders (DC/TBD)

System/Concern	Evaluation	Comment
Dermatologic	Thorough skin & nail exam	
Dental	Baseline eval for oral hygiene, leukoplakia, & oral squamous cell cancer	
Otolaryngologic	Baseline eval for leukoplakia & squamous cell head/neck cancer	
Growth & development	Clinical assessment	
Ophthalmic	Thorough exam for complications related to lacrimal duct stenosis, abnormal eyelash growth, & retinal disorders incl exudative retinopathy	
Gastrointestinal & hepatic	History of potential swallowing difficulties &/or enteropathy; baseline liver function tests	
Genitourinary	For males, assessment for urethral stenosis	
Musculoskeletal	Consideration of baseline bone mineral density scan at age 14 yrs or at diagnosis; history of any joint problems	
Neurologic	If early-onset neurologic findings (e.g., ataxia) or many complications are found in other initial evals, consider brain MRI to evaluate for cerebellar hypoplasia or intracranial calcifications.	
Hematologic	Eval by hematologist incl CBC & bone marrow aspiration & biopsy to determine if signs of BMF are present	Consideration of HLA typing of affected person, unaffected sibs, & parents in anticipation of possible need for HCT
Pulmonary	<ul style="list-style-type: none"> Baseline PFTs incl carbon monoxide diffusion capacity Consider bubble echocardiography to evaluate for pulmonary arteriovenous malformations. 	Eval by pulmonologist if patient is symptomatic or PFTs are abnormal
Increased risk of cancer	<ul style="list-style-type: none"> Eval by otolaryngologist & dentist as soon as patient is able to cooperate w/exam Gynecologic exam for females starting by age 16 yrs or when sexually active 	

Table 5. continued from previous page.

System/Concern	Evaluation	Comment
Immunologic	<ul style="list-style-type: none"> Lymphocyte subsets, lymphocyte proliferation response, serum IgG, IgM, IgA levels If presenting w/↑ infections: tetanus/diphtheria/poliomyelitis/pneumococcal antibodies & IgM isohemagglutinin titer 	
Cardiologic	Baseline eval for cardiac malformations	
Genetic counseling	By genetics professionals ¹	To inform affected persons & their families re nature, MOI, & implications of DC/TBD to facilitate medical & personal decision making
Family support & resources	Assess need for: <ul style="list-style-type: none"> Community resources such as Team Telomere or DC Action (in UK); Social work involvement for parental support; Home nursing referral. 	

BMF = bone marrow failure; CBC = complete blood count; HCT = hematopoietic cell transplantation; MOI = mode of inheritance; PFT = pulmonary function test

1. Medical geneticist, certified genetic counselor, certified advanced genetic nurse

Treatment of Manifestations

The specific treatment for DC/TBD-related complications must be tailored to the individual. The recommendations in this section were first discussed at a DC clinical research workshop in 2008 and subsequently at a meeting of experts convened to review the publication of the first edition of the *Dyskeratosis Congenita and Telomere Biology Disorders: Diagnosis and Management Guidelines* [Savage et al 2009, Savage & Cook 2015]. Because of the rarity of DC/TBD, the recommendations are not based on large-scale clinical trials. Affected individuals may have few or many of the complications associated with DC/TBD. Comprehensive coordinated care among specialties is required.

Clinical care guidelines are also available at [Team Telomere](#).

Table 6. Treatment of Manifestations in Individuals with Dyskeratosis Congenita and Related Telomere Biology Disorders (DC/TBD)

Manifestation/Concern	Treatment	Considerations/Other
Bone marrow failure ¹	If matched related donor is available: HCT ² regardless of age	<ul style="list-style-type: none"> • Range of clinical phenotypes seen in DC/TBD & possibility of non-manifesting or very mildly affected heterozygotes w/in families may complicate selection of related HCT donors. ³ • Test potential related HCT donors either for pathogenic variant(s) present in proband or, if variant(s) are unknown, for telomere length.
	If matched related donor is not available: HCT ² from unrelated donor can be considered, although trial of androgen therapy (e.g., oxymetholone or danazol) may be considered 1st. ⁴	<ul style="list-style-type: none"> • Persons w/DC/TBD may be more sensitive to androgens than those w/FA, & dose must be adjusted to ↓ side effects such as impaired liver function, virilization, or behavior problems (e.g., aggression, mood swings). • Side effects, incl liver enzyme abnormalities, need to be monitored carefully. • Perform baseline & follow-up liver ultrasound exams for persons receiving androgen therapy because of possibility of liver adenomas & carcinomas, which have been reported in FA & in persons using androgens for benign hematologic diseases or for non-hematologic disorders. ⁵
	Hematopoietic growth factors	Should not be combined w/androgen therapy due to possible risk of splenic peliosis & rupture
Cancer	Specific treatment should be tailored to type of cancer.	<p>Affected persons undergoing chemotherapy for cancer may be at ↑ risk for:</p> <ul style="list-style-type: none"> • Prolonged cytopenias due to underlying BMF; • Therapy-related pulmonary & hepatic toxicity (PFTs & liver function should be monitored carefully); • Radiotherapy-related complications based on observations in persons undergoing radiotherapy in HCT. ⁶
Pulmonary fibrosis	Primarily supportive care	Lung transplantation may be considered in severe cases, although long-term outcomes have not been studied. ⁷
Liver disease	Primarily supportive care	Liver transplant may be considered in severe cases, although data on outcome are scarce.
General health	Childhood vaccinations (unless contraindicated due to immunodeficiency or HCT) incl influenza & human papillomavirus	

BMF = bone marrow failure; FA = Fanconi anemia; HCT = hematopoietic cell transplantation; PFT = pulmonary function test

1. Following the model of the Fanconi anemia consensus guidelines [Eiler et al 2008] and updated in the DC treatment guidelines [Savage & Cook 2015], treatment of bone marrow failure (BMF) is recommended if the hemoglobin is consistently below 8 g/dL, platelets are lower than 30,000/mm³, and neutrophils are below 1,000/mm³.

2. HCT is the only curative treatment for severe BMF or leukemia in DC/TBD. It should be performed at centers experienced in treating DC/TBD. Pre- and post-transplant considerations and outcomes have been recently reviewed [Fioredda et al 2018, Bonfim 2020].

3. Fogarty et al [2003], Denny et al [2008]

4. Khincha et al [2014], Townsley et al [2016]

5. Velazquez & Alter [2004]

6. Author, personal observation

7. See [Familial Pulmonary Fibrosis](#).

Surveillance

The recommendations in this section were discussed at the first DC clinical research workshop in 2008 and updated in 2014 at a consensus conference that led to publication of the first edition of the *Dyskeratosis Congenita and Telomere Biology Disorders: Diagnosis and Management Guidelines* [Savage et al 2009, Savage & Cook 2015]. Because of the rarity of DC/TBD, the recommendations are not based on large-scale clinical trials.

Table 7. Recommended Surveillance for Individuals with Dyskeratosis Congenita and Related Telomere Biology Disorders (DC/TBD)

System/Concern	Evaluation	Frequency
Bone marrow failure	<ul style="list-style-type: none"> CBC Bone marrow aspirate & biopsy incl morphologic exam & cytogenetic studies 	<ul style="list-style-type: none"> Annually More frequently in case of ↓ blood count detection of clonal cytogenetic abnormality ¹
Androgen therapy for BMF	CBC	<ul style="list-style-type: none"> Prior to start Rpt every 4-6 wks When counts are stable, rpt every 2-3 mos
	Liver function tests	Prior to start & then every 6-12 wks
	Liver ultrasound	Prior to start & then every 6 mos
	Cholesterol & triglycerides	
	Endocrinology eval	Prior to start & then annually for side effects
Cancer	Self-exam for oral, head, & neck cancers	Monthly
	<ul style="list-style-type: none"> Cancer screening by otolaryngologist Gynecologic exam Skin cancer screening by dermatologist 	Annually
Pulmonary fibrosis	PFTs	Annually starting at age 8 yrs (or at diagnosis)
Pulmonary arteriovenous malformations	Bubble echocardiogram	In case of pulmonary symptoms in absence of pulmonary fibrosis
Oral & dental issues	<ul style="list-style-type: none"> Exam by dentist & dental hygienist Monitoring of leukoplakia & biopsy of suspicious lesions 	Every 6 mos
Immunologic issues	Follow up based on findings at initial eval	At immunologist's discretion
Cutaneous manifestations	Full-body skin exam by dermatologist	Annually
Developmental delay	Clinical eval & referral to specialist if needed	At each visit in childhood
Ophthalmologic problems	Ophthalmologic exam (vision problems, abnormally growing eyelashes, lacrimal duct stenosis, retinal changes, bleeding, cataracts, & glaucoma)	Annually
Avascular osteonecrosis	Clinical eval based on symptoms	At each visit
Liver disease	Liver function tests (irrespective of androgen therapy)	Annually

BMF = bone marrow failure; CBC = complete blood count; PFT = pulmonary function test

1. Including 5q-, 7q-/monosomy 7, trisomy 8, 20q-, 11q23 translocation, 3q abnormalities

Agents/Circumstances to Avoid

Blood transfusions

- Transfusions of red cells or platelets should be avoided or minimized for those who are candidates for hematopoietic cell transplantation (HCT).
- To minimize the chances of sensitization, family members must not act as blood donors if HCT is being considered.
- All blood products should be leukodepleted and irradiated.

Radiation. It is prudent to minimize exposure to therapeutic radiation as data on radiation side effects are limited.

Androgens and growth factors. The combination of androgens and granulocyte colony-stimulating factor was associated with splenic peliosis ("blood lakes") and rupture in two individuals; thus, the combination should be avoided [Giri et al 2007].

Cancer prevention. Given the increased susceptibility of individuals with DC/TBD to developing leukemias and other malignancies, individuals with DC/TBD are advised to avoid toxic agents that have been implicated in tumorigenesis (including smoking cigarettes or drinking alcohol), to use sunscreen regularly, and to avoid excessive sun exposure.

Evaluation of Relatives at Risk

For early diagnosis and treatment. It is appropriate to evaluate apparently asymptomatic older and younger at-risk relatives of an affected individual in order to identify as early as possible those who would benefit from preventive measures, hematologic surveillance, and prompt initiation of treatment.

Evaluations include:

- Telomere length testing;
- Molecular genetic testing if a molecular diagnosis has been established in the proband.

For hematopoietic cell transplantation (HCT) donor evaluation. Any relative who is a potential HCT donor should undergo telomere length testing or molecular genetic testing (if the pathogenic variant[s] in the family are known).

See Genetic Counseling for issues related to testing of at-risk relatives for genetic counseling purposes.

Pregnancy Management

Individuals with DC/TBD who become pregnant may develop pancytopenia or existing cytopenias may worsen. They should be followed closely by a perinatologist.

Therapies Under Investigation

Search [ClinicalTrials.gov](https://clinicaltrials.gov) in the US and [EU Clinical Trials Register](https://clinicaltrialsregister.eu) in Europe for information on clinical studies for a wide range of diseases and conditions. Note: There may not be clinical trials for this disorder.

Genetic Counseling

Genetic counseling is the process of providing individuals and families with information on the nature, mode(s) of inheritance, and implications of genetic disorders to help them make informed medical and personal decisions. The following section deals with genetic risk assessment and the use of family history and genetic testing to clarify genetic status for family members; it is not meant to address all personal, cultural, or ethical issues that may arise or to substitute for consultation with a genetics professional. —ED.

Mode of Inheritance

The mode of inheritance of dyskeratosis congenita and related telomere biology disorders (DC/TBD) depends on the associated gene (see Table 8).

Table 8. Dyskeratosis Congenita and Related Telomere Biology Disorders (DC/TBD): Mode of Inheritance by Gene

Gene ¹	Mode of Inheritance
<i>ACD</i>	AD or AR
<i>CTC1</i>	AR
<i>DKC1</i>	XL
<i>NAF1</i>	AD
<i>NHP2</i>	AR
<i>NOPI0</i>	AR
<i>PARN</i>	AD or AR
<i>POT1</i>	AR
<i>RPA1</i>	AD
<i>RTEL1</i>	AD or AR
<i>STN1</i>	AR
<i>TERC</i>	AD
<i>TERT</i>	AD or AR
<i>TINF2</i>	AD
<i>WRAP53</i>	AR
<i>ZCCHC8</i>	AD

AD = autosomal dominant; AR = autosomal recessive; XL = X-linked

1. Genes are listed in alphabetic order.

Note: If the causative pathogenic variant(s) have not been identified in an affected family member, telomere length testing of first-degree relatives is recommended (see Management, Evaluation of Relatives at Risk).

X-Linked Inheritance – Risk to Family Members

Parents of a male proband

- The father of an affected male will not have the disorder nor will he be hemizygous for the *DKC1* pathogenic variant; therefore, he does not require further evaluation/testing.
- In a family with more than one affected male, the mother of an affected male is an obligate heterozygote. If a woman has more than one affected child and the *DKC1* pathogenic variant cannot be detected in her leukocyte DNA, she most likely has germline mosaicism.
- If a male is the only affected family member (i.e., a simplex case), the mother may be a heterozygote, the affected male may have a *de novo* pathogenic variant (in which case the mother is not a heterozygote), or the mother may have somatic/germline mosaicism.
- Molecular genetic testing of the mother is recommended to confirm her genetic status and to allow reliable recurrence risk assessment.

Sibs of a male proband. The risk to sibs depends on the genetic status of the mother:

- If the mother of the proband has a pathogenic variant, the chance of transmitting it in each pregnancy is 50%:
 - Males who inherit the pathogenic variant will be affected.
 - Females who inherit the pathogenic variant will be heterozygotes. Clinical manifestations in females heterozygous for *DKC1* pathogenic variants have been reported, including skin pigmentation abnormalities, nail dysplasia, and bone marrow failure [Vulliamy et al 2006, Xu et al 2016, Hirvonen et al 2019].
- If the proband represents a simplex case and if the *DKC1* pathogenic variant cannot be detected in the leukocyte DNA of the mother, the risk to sibs is presumed to be low but greater than that of the general population because of the possibility of maternal germline mosaicism.

Offspring of a male proband. Affected males transmit the *DKC1* pathogenic variant to:

- All their daughters, who will be heterozygotes;
- None of their sons.

Other family members. The maternal aunts and maternal cousins of a male proband may be at risk of having a *DKC1* pathogenic variant.

Heterozygote detection. Heterozygote testing for at-risk female relatives requires prior identification of the *DKC1* pathogenic variant in the family.

Autosomal Dominant Inheritance – Risk to Family Members

Parents of a proband

- Some individuals diagnosed with autosomal dominant DC/TBD have an affected parent.
- A proband with autosomal dominant DC/TBD may have the disorder as the result of a *de novo* DC/TBD-causing pathogenic variant. With the exception of *TINF2* – in which the majority of pathogenic variants appear to occur *de novo* in the proband [Savage et al 2008, Walne et al 2008, Sasa et al 2012] – the proportion of individuals with DC/TBD caused by a *de novo* pathogenic variant is unknown.
- If the causative pathogenic variant has been identified in the proband and the proband appears to be the only affected family member (i.e., a simplex case), molecular genetic testing is recommended for the parents of the proband to confirm their genetic status and to allow reliable recurrence risk counseling. If the causative pathogenic variant has not been identified in the proband, telomere length testing of the parents is recommended.
- If the proband has a known pathogenic variant that cannot be detected in either parent and parental identity testing has confirmed biological maternity and paternity, the following possibilities should be considered:
 - The proband has a *de novo* pathogenic variant.
 - The proband inherited a pathogenic variant from a parent with germline mosaicism. Note: Testing of parental leukocyte DNA may not detect all instances of somatic mosaicism and will not detect a pathogenic variant that is present in the germ cells only. Walne et al [2008] reported a family with two affected sibs, in one of whom a *TINF2* pathogenic variant was identified (the other was deceased and could not be tested); neither parent had the pathogenic variant, suggesting germline mosaicism in a parent.
 - The proband inherited a DC/TBD-causing pathogenic variant from a parent with somatically acquired loss of heterozygosity with preferential loss of the chromosome with the pathogenic variant. This scenario may cause a false negative molecular result when testing leukocyte DNA. Note: To date, this has only been observed in individuals with germline *TERC* or *RPA1* pathogenic variants.

- The family history of some individuals diagnosed with autosomal dominant DC/TBD may appear to be negative because of a milder phenotypic presentation. Therefore, an apparently negative family history cannot be confirmed without molecular genetic testing (to establish that neither parent is heterozygous for the pathogenic variant identified in the proband).

Sibs of a proband. The risk to the sibs of the proband depends on the clinical/genetic status of the proband's parents:

- If a parent of the proband is affected and/or is known to have the pathogenic variant identified in the proband, the risk to the sibs of inheriting the pathogenic variant is 50%. The age of onset and manifestations of DC/TBD may vary considerably among heterozygous family members (see Penetrance).
- If the DC/TBD-causing pathogenic variant found in the proband cannot be detected in the DNA of either parent, the recurrence risk to sibs is slightly greater than that of the general population because of:
 - The possibility of parental germline mosaicism [Walne et al 2008]; or
 - A false negative result in a parent due to preferential loss of the chromosome with the DC/TBD-causing pathogenic variant. Note: Revertant mosaicism (i.e., loss of heterozygosity for the deleterious allele) in peripheral blood cells has only been observed in individuals with germline *TERC* or *RPA1* pathogenic variants.
- If the parents are clinically unaffected but they have not undergone molecular genetic testing or telomere testing, sibs are presumed to be at increased risk for DC/TBD for one of two possible reasons:
 - A parent has germline mosaicism; or
 - A parent is heterozygous but does not have apparent manifestations of DC/TBD because of phenotypic modification resulting from additional genetic events that confer a protective effect.

Offspring of a proband. Each child of an individual with autosomal dominant DC/TBD has a 50% chance of inheriting the DC/TBD-causing pathogenic variant.

Other family members. The risk to other family members depends on the status of the proband's parents: if a parent is affected, his or her family members may be at risk of having the DC/TBD-causing pathogenic variant and the associated clinical manifestations including leukemia and squamous cell cancer (see Clinical Description).

Autosomal Recessive Inheritance – Risk to Family Members

Parents of a proband

- The parents of an affected child are presumed to be heterozygous for one DC/TBD-causing pathogenic variant.
- If the causative pathogenic variants have been identified in the proband, molecular genetic testing is recommended for the parents of the proband to confirm that both parents are heterozygous for a DC/TBD-causing pathogenic variant and to allow reliable recurrence risk assessment.
- If a pathogenic variant is detected in only one parent and parental identity testing has confirmed biological maternity and paternity, it is possible that one of the pathogenic variants identified in the proband occurred as a *de novo* event in the proband or as a postzygotic *de novo* event in a mosaic parent [Jónsson et al 2017]. If the proband appears to have homozygous pathogenic variants (i.e., the same two pathogenic variants), additional possibilities to consider include:
 - A single- or multiexon deletion in the proband that was not detected by sequence analysis and that resulted in the artifactual appearance of homozygosity;
 - Uniparental isodisomy for the parental chromosome with the pathogenic variant that resulted in homozygosity for the pathogenic variant in the proband.
- Heterozygotes may or not may not be affected.

- Pathogenic variants in *ACD*, *PARN*, *RTEL*, or *TERT* can cause both autosomal dominant and autosomal recessive DC/TBD; the effect of heterozygosity for one *ACD*, *PARN*, *RTEL*, or *TERT* pathogenic variant in individuals from families in which DC/TBD has been inherited in an autosomal recessive manner has not been thoroughly studied, but these individuals may be at elevated risk of DC/TBD-related complications.
- Heterozygotes for a pathogenic variant in *CTC1*, *NHP2*, *NOP10*, *PARN*, *POT1*, or *WRAP53* are predicted to be asymptomatic for DC/TBD manifestations. Individuals who are heterozygous for a *POT1* pathogenic variant should be evaluated for *POT1* tumor predisposition.

Sibs of a proband

- If both parents are known to be heterozygous for a DC/TBD-causing pathogenic variant, each sib of an affected individual has at conception a 25% chance of inheriting two DC/TBD-causing pathogenic variants, a 50% chance of inheriting one pathogenic variant, and a 25% chance of inheriting neither of the familial DC/TBD-causing pathogenic variants.
- The age of onset and manifestations of DC/TBD may vary considerably among family members with biallelic pathogenic variants.
- Heterozygotes may or not may not be affected.
 - Pathogenic variants in *ACD*, *PARN*, *RTEL*, or *TERT* can cause both autosomal dominant and autosomal recessive DC/TBD; the effect of heterozygosity for one *ACD*, *PARN*, *RTEL*, or *TERT* pathogenic variant in individuals from families in which DC/TBD has been inherited in an autosomal recessive manner has not been thoroughly studied but these individuals may be at elevated risk of DC/TBD-related complications.
 - Heterozygotes for a pathogenic variant in *CTC1*, *NHP2*, *NOP10*, *PARN*, *POT1*, or *WRAP53* are predicted to be asymptomatic for DC/TBD manifestations. Individuals who are heterozygous for a *POT1* pathogenic variant should be evaluated for *POT1* tumor predisposition.

Offspring of a proband. The offspring of an individual with autosomal recessive DC/TBD are obligate heterozygotes for a DC/TBD-related pathogenic variant.

Other family members. Each sib of the proband's parents is at a 50% risk of being heterozygous for a DC/TBD-related pathogenic variant.

Heterozygote detection. Heterozygote testing for at-risk relatives requires prior identification of the DC/TBD-related pathogenic variants in the family.

Related Genetic Counseling Issues

See Management, Evaluation of Relatives at Risk for information on evaluating at-risk relatives for the purpose of early diagnosis, treatment, and evaluation as a potential hematopoietic cell transplantation donor.

Predictive testing for at-risk asymptomatic family members requires prior identification of the pathogenic variant(s) in the family or, if the causative pathogenic variant(s) in the family are unknown, documentation of short telomere length in an affected relative.

Family planning

- The optimal time for determination of genetic risk and discussion of the availability of prenatal/preimplantation genetic testing is before pregnancy.
- It is appropriate to offer genetic counseling (including discussion of potential risks to offspring and reproductive options) to young adults who are affected, are heterozygous, or are at risk of being heterozygous.

DNA banking. Because it is likely that testing methodology and our understanding of genes, pathogenic mechanisms, and diseases will improve in the future, consideration should be given to banking DNA from probands in whom a molecular diagnosis has not been confirmed (i.e., the causative pathogenic mechanism is unknown). For more information, see Huang et al [2022].

Prenatal Testing and Preimplantation Genetic Testing

Once the DC/TBD-related pathogenic variant(s) have been identified in an affected family member, prenatal and preimplantation genetic testing are possible.

Differences in perspective may exist among medical professionals and within families regarding the use of prenatal testing. While most centers would consider use of prenatal testing to be a personal decision, discussion of these issues may be helpful.

Resources

GeneReviews staff has selected the following disease-specific and/or umbrella support organizations and/or registries for the benefit of individuals with this disorder and their families. GeneReviews is not responsible for the information provided by other organizations. For information on selection criteria, click [here](#).

- DC Action**
 United Kingdom
Email: info@dcaction.org
www.dcaction.org
- Team Telomere**
 1562 First Avenue #205-4093
 New York NY 10028-4004
Email: info@teamtelomere.org
www.teamtelomere.org
- National Cancer Institute Inherited Bone Marrow Failure Syndromes (IBMFS) Cohort Registry**
Phone: 800-518-8474
Email: NCI.IBMFS@westat.com
marrowfailure.cancer.gov

Molecular Genetics

Information in the Molecular Genetics and OMIM tables may differ from that elsewhere in the GeneReview: tables may contain more recent information. —ED.

Table A. Dyskeratosis Congenita and Related Telomere Biology Disorders: Genes and Databases

Gene	Chromosome Locus	Protein	Locus-Specific Databases	HGMD	ClinVar
<i>ACD</i>	16q22.1	Adrenocortical dysplasia protein homolog		ACD	ACD
<i>CTC1</i>	17p13.1	CST complex subunit CTC1	CTC1 @ LOVD	CTC1	CTC1

Table A. continued from previous page.

<i>DKC1</i>	Xq28	H/ACA ribonucleoprotein complex subunit DKC1	DKC1 @ LOVD Telomerase Database (DKC1) DKC1base: Mutation registry for Hoyeraal-Hreidarsson syndrome	DKC1	DKC1
<i>NAF1</i>	4q32.2	H/ACA ribonucleoprotein complex non-core subunit NAF1		NAF1	NAF1
<i>NHP2</i>	5q35.3	H/ACA ribonucleoprotein complex subunit 2	Telomerase Database, Nola2 (NHP2) mutations NHP2 database	NHP2	NHP2
<i>NOP10</i>	15q14	H/ACA ribonucleoprotein complex subunit 3	Telomerase Database, Nola3 (Nop10) mutations NOP10 database	NOP10	NOP10
<i>PARN</i>	16p13.12	Poly(A)-specific ribonuclease PARN		PARN	PARN
<i>POT1</i>	7q31.33	Protection of telomeres protein 1		POT1	POT1
<i>RPA1</i>	17p13.3	Replication protein A 70 kDa DNA-binding subunit		RPA1	RPA1
<i>RTEL1</i>	20q13.33	Regulator of telomere elongation helicase 1		RTEL1	RTEL1
<i>STN1</i>	10q24.33	CST complex subunit STN1		STN1	STN1
<i>TERC</i>	3q26.2	Not applicable	Telomerase Database, TR mutations (TERC)	TERC	TERC
<i>TERT</i>	5p15.33	Telomerase reverse transcriptase	Telomerase Database (TERT) TERT database	TERT	TERT
<i>TINF2</i>	14q12	TERF1-interacting nuclear factor 2	Telomerase Database, TINF2 mutations TINF2 database	TINF2	TINF2
<i>WRAP53</i>	17p13.1	Telomerase Cajal body protein 1	Telomerase Database (WRAP53)	WRAP53	WRAP53
<i>ZCCHC8</i>	12q24.31	Zinc finger CCHC domain-containing protein 8		ZCCHC8	ZCCHC8

Data are compiled from the following standard references: gene from [HGNC](#); chromosome locus from [OMIM](#); protein from [UniProt](#). For a description of databases (Locus Specific, HGMD, ClinVar) to which links are provided, click [here](#).

Table B. OMIM Entries for Dyskeratosis Congenita and Related Telomere Biology Disorders (View All in OMIM)

127550	DYSKERATOSIS CONGENITA, AUTOSOMAL DOMINANT 1; DKCA1
179835	REPLICATION PROTEIN A1, 70-KD; RPA1
187270	TELOMERASE REVERSE TRANSCRIPTASE; TERT
224230	DYSKERATOSIS CONGENITA, AUTOSOMAL RECESSIVE 1; DKCB1
268130	REVESZ SYNDROME

Table B. continued from previous page.

300126	DYSKERIN; DKC1
305000	DYSKERATOSIS CONGENITA, X-LINKED; DKCX
602322	TELOMERASE RNA COMPONENT; TERC
604212	POLYADENYLATE-SPECIFIC RIBONUCLEASE; PARN
604319	TERF1-INTERACTING NUCLEAR FACTOR 2; TINF2
606470	NHP2 RIBONUCLEOPROTEIN; NHP2
606471	NOP10 RIBONUCLEOPROTEIN; NOP10
606478	PROTECTION OF TELOMERES 1; POT1
608833	REGULATOR OF TELOMERE ELONGATION HELICASE 1; RTEL1
609377	ACD SHELTERIN COMPLEX SUBUNIT AND TELOMERASE RECRUITMENT FACTOR; ACD
612199	CEREBRORETINAL MICROANGIOPATHY WITH CALCIFICATIONS AND CYSTS 1; CRMCC1
612661	WD REPEAT-CONTAINING PROTEIN ANTISENSE TO TP53; WRAP53
613128	STN1, CST COMPLEX SUBUNIT; STN1
613129	CONSERVED TELOMERE MAINTENANCE COMPONENT 1; CTC1
613987	DYSKERATOSIS CONGENITA, AUTOSOMAL RECESSIVE 2; DKCB2
613988	DYSKERATOSIS CONGENITA, AUTOSOMAL RECESSIVE 3; DKCB3
613989	DYSKERATOSIS CONGENITA, AUTOSOMAL DOMINANT 2; DKCA2
613990	DYSKERATOSIS CONGENITA, AUTOSOMAL DOMINANT 3; DKCA3
615190	DYSKERATOSIS CONGENITA, AUTOSOMAL RECESSIVE 5; DKCB5
616353	DYSKERATOSIS CONGENITA, AUTOSOMAL RECESSIVE 6; DKCB6
616381	ZINC FINGER CCHC DOMAIN-CONTAINING PROTEIN 8; ZCCHC8
616553	DYSKERATOSIS CONGENITA, AUTOSOMAL DOMINANT 6; DKCA6
617341	CEREBRORETINAL MICROANGIOPATHY WITH CALCIFICATIONS AND CYSTS 2; CRMCC2
617868	NUCLEAR ASSEMBLY FACTOR 1 RIBONUCLEOPROTEIN; NAF1
618674	PULMONARY FIBROSIS AND/OR BONE MARROW FAILURE SYNDROME, TELOMERE-RELATED, 5; PFBMFT5
619767	PULMONARY FIBROSIS AND/OR BONE MARROW FAILURE SYNDROME, TELOMERE-RELATED, 6; PFBMFT6
620365	PULMONARY FIBROSIS AND/OR BONE MARROW FAILURE SYNDROME, TELOMERE-RELATED, 7; PFBMFT7

Molecular Pathogenesis

Dyskeratosis congenita and related telomere biology disorders (DC/TBD) are caused by impaired telomere maintenance resulting in short or very short telomeres. The telomere is a complex structure consisting of long nucleotide repeats (TTAGGG)_n and a protein complex at chromosome ends that are essential to chromosomal integrity. The TTAGGG nucleotide repeats at the chromosome end fold back to create a T-loop. Many proteins bind to the T-loop and others bind to those proteins to form a stable telomere "cap." Pathogenic variants in 16 different genes (*ACD*, *CTC1*, *DKC1*, *NAF1*, *NHP2*, *NOP10*, *PARN*, *POT1*, *RPA1*, *RTEL1*, *STN1*, *TERC*, *TERT*, *TINF2*, *WRAP53*, and *ZCCHC8*) encoding critical components of the telomere have been found in individuals with DC/TBD (Figure 3).

Mechanism of disease causation. DC/TBD are caused by a loss-of-function mechanism [Bertuch 2016].

Notable variants by gene. See Table 9.

Note: The [Telomerase Database](#), which is maintained by the Arizona State University, is a widely used tool in the telomere research community. Specifically, it includes a collection of variants published in the context of DC/TBD that may be useful in interpreting detected variants in individuals with suspected DC/TBD [Podlevsky et al 2008].

Table 9. DC/TBD: Notable Pathogenic Variants by Gene

Gene ¹	Reference Sequences	DNA Nucleotide Change	Predicted Protein Change	Comment [Reference]
<i>RTEL1</i>	NM_001283009.2 NP_001269938.1	c.3791G>A	p.Arg1264His	Founder variant in persons of Ashkenazi Jewish ancestry [Shi et al 2017]
<i>TERT</i>	NM_198253.3 NP_937983.2	c.2005C>T	p.Arg669Trp	Founder variant in persons of Dutch ancestry [van der Vis et al 2020]

Variants listed in the table have been provided by the authors. *GeneReviews* staff have not independently verified the classification of variants.

GeneReviews follows the standard naming conventions of the Human Genome Variation Society (varnomen.hgvs.org). See [Quick Reference](#) for an explanation of nomenclature.

1. Genes from Table 1 are in alphabetic order.

Chapter Notes

Author Notes

Website: marrowfailure.cancer.gov

Acknowledgments

Drs Blanche Alter, Neelam Giri, and Lisa McReynolds, NCI, contributed invaluable advice and insight into patient diagnosis and management.

This work was supported (in part) by the intramural research program of the National Cancer Institute, National Institutes of Health.

Revision History

- 19 January 2023 (sw/sas) Revision: updated number of families with pathogenic variants in *WRAP53* detected by sequence analysis (see Table 1)
- 31 March 2022 (ha) Comprehensive update posted live
- 21 November 2019 (aa) Revision: added mode of inheritance and OMIM links for idiopathic pulmonary fibrosis
- 26 May 2016 (ha) Comprehensive update posted live
- 3 January 2013 (cd) Revision: mutations in *CTCI* found to cause dyskeratosis congenita
- 13 September 2012 (cd) Revision: sequence analysis of the entire coding regions of *NHP2* and *NOP10* available clinically
- 10 May 2012 (me) Comprehensive update posted live
- 12 November 2009 (me) Review posted live
- 15 May 2009 (sas) Original submission

Pursuant to 17 USC Section 105 of the United States Copyright Act, the *GeneReview* "Dyskeratosis Congenita and Related Telomere Biology Disorders" is in the public domain in the United States of America.

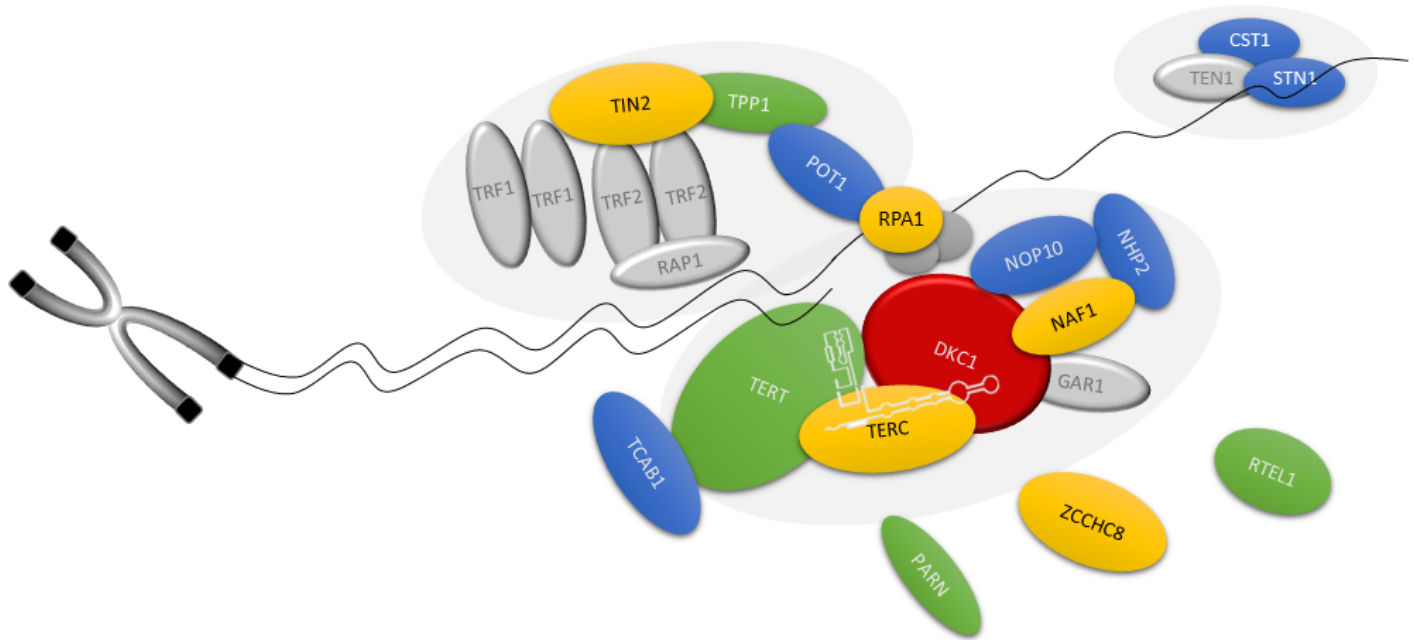


Figure 3. Schematic of the telomere and the proteins affected in dyskeratosis congenita and related telomere biology disorders

Colors refer to reported inheritance pattern in the coding genes of depicted proteins:

Red = X-linked

Blue = autosomal recessive

Yellow = autosomal dominant

Green = autosomal dominant and autosomal recessive inheritance reported

Gray = not known to cause human disease

References

Literature Cited

- Alter BP, Giri N, Savage SA, Rosenberg PS. Cancer in the National Cancer Institute inherited bone marrow failure syndrome cohort after fifteen years of follow-up. *Haematologica*. 2018;103:30–9. PubMed PMID: 29051281.
- Alter BP, Rosenberg PS, Giri N, Baerlocher GM, Lansdorp PM, Savage SA. Telomere length is associated with disease severity and declines with age in dyskeratosis congenita. *Haematologica*. 2012;97:353–9. PubMed PMID: 22058220.
- Anderson BH, Kasher PR, Mayer J, Szykiewicz M, Jenkinson EM, Bhaskar SS, Urquhart JE, Daly SB, Dickerson JE, O'Sullivan J, Leibundgut EO, Muter J, Abdel-Salem GM, Babul-Hirji R, Baxter P, Berger A, Bonafé L, Brunstom-Hernandez JE, Buckard JA, Chitayat D, Chong WK, Cordelli DM, Ferreira P, Fluss J, Forrest EH, Franzoni E, Garone C, Hammans SR, Houge G, Hughes I, Jacquemont S, Jeannet PY, Jefferson RJ, Kumar R, Kutschke G, Lundberg S, Lourenço CM, Mehta R, Naidu S, Nischal KK, Nunes L, Ounap K, Philippart M, Prabhakar P, Risen SR, Schiffmann R, Soh C, Stephenson JB, Stewart H, Stone J, Tolmie JL, van der Knaap MS, Vieira JP, Vilain CN, Wakeling EL, Wermenbol V, Whitney A, Lovell SC, Meyer S, Livingston JH, Baerlocher GM, Black GC, Rice GI, Crow YJ. Mutations in CTC1, encoding conserved telomere maintenance component 1, cause Coats plus. *Nat Genet*. 2012;44:338–42. PubMed PMID: 22267198.

- Armanios MY, Chen JJ, Cogan JD, Alder JK, Ingersoll RG, Markin C, Lawson WE, Xie M, Vulto I, Phillips JA III, Lansdorp PM, Greider CW, Loyd JE. Telomerase mutations in families with idiopathic pulmonary fibrosis. *N Engl J Med*. 2007;356:1317–26. PubMed PMID: 17392301.
- Ballew BJ, Savage SA. Updates on the biology and management of dyskeratosis congenita and related telomere biology disorders. *Expert Rev Hematol*. 2013;2013;6:327–37. PubMed PMID: 23782086.
- Balogh E, Chandler JC, Varga M, Tahoun M, Menyhárd DK, Schay G, Goncalves T, Hamar R, Légrádi R, Szekeres Á, Gribouval O, Kleta R, Stanescu H, Bockenbauer D, Kerti A, Williams H, Kinsler V, Di WL, Curtis D, Kolatsi-Joannou M, Hammid H, Szócs A, Perczel K, Maka E, Toldi G, Sava F, Arrondel C, Kardos M, Fintha A, Hossain A, D'Arco F, Kaliakatsos M, Koeglmeier J, Mifsud W, Moosajee M, Faro A, Jávorszky E, Rudas G, Saied MH, Marzouk S, Kelen K, Götze J, Reusz G, Tulassay T, Dragon F, Mollet G, Motameny S, Thiele H, Dorval G, Nürnberg P, Perczel A, Szabó AJ, Long DA, Tomita K, Antignac C, Waters AM, Tory K. Pseudouridylation defect due to DKC1 and NOP10 mutations causes nephrotic syndrome with cataracts, hearing impairment, and enterocolitis. *Proc Natl Acad Sci U S A*. 2020;117:15137–47. PubMed PMID: 32554502.
- Belaya Z, Golounina O, Nikitin A, Tarbaeva N, Pigarova E, Mamedova E, Vorontsova M, Shafieva I, Demina I, Van Hul W. Multiple bilateral hip fractures in a patient with dyskeratosis congenita caused by a novel mutation in the PARN gene. *Osteoporos Int*. 2021;32:1227–31. PubMed PMID: 33244623.
- Benyelles M, O'Donohue MF, Kermasson L, Lainey E, Borie R, Lagresle-Peyrou C, Nunes H, Cazelles C, Fourrage C, Ollivier E, Marcais A, Gamez AS, Morice-Picard F, Caillaud D, Pottier N, Ménard C, Ba I, Fernandes A, Crestani B, de Villartay JP, Gleizes PE, Callebaut I, Kannengiesser C, Revy P. NHP2 deficiency impairs rRNA biogenesis and causes pulmonary fibrosis and Høyeraal-Hreidarsson syndrome. *Hum Mol Genet*. 2020;29:907–22. PubMed PMID: 31985013.
- Bergstrand S, Böhm S, Malmgren H, Norberg A, Sundin M, Nordgren A, Farnebo M. Biallelic mutations in WRAP53 result in dysfunctional telomeres, Cajal bodies and DNA repair, thereby causing Høyeraal-Hreidarsson syndrome. *Cell Death Dis*. 2020;11:238. PubMed PMID: 32303682.
- Bertuch AA. The molecular genetics of the telomere biology disorders. *RNA Biol*. 2016;13:696–706. PubMed PMID: 26400640.
- Bhala S, Best AF, Giri N, Alter BP, Pao M, Gropman A, Baker EH, Savage SA. CNS manifestations in patients with telomere biology disorders. *Neurol Genet*. 2019;5:370. PubMed PMID: 31872047.
- Bonfim C. Special pre- and posttransplant considerations in inherited bone marrow failure and hematopoietic malignancy predisposition syndromes. *Hematology Am Soc Hematol Educ Program*. 2020;2020:107–14. PubMed PMID: 33275667.
- Brailovski E, Tsui H, Chen YB, Velsher L, Liu J, Buckstein R. Previously unreported WRAP53 gene variants in a patient with dyskeratosis congenita. *Ann Hematol*. 2022;101:907–9. PubMed PMID: 34599657.
- Briggs TA, Abdel-Salam GM, Balicki M, Baxter P, Bertini E, Bishop N, Browne BH, Chitayat D, Chong WK, Eid MM, Halliday W, Hughes I, Klusmann-Koy A, Kurian M, Nischal KK, Rice GI, Stephenson JB, Surtees R, Talbot JF, Tehrani NN, Tolmie JL, Toomes C, van der Knaap MS, Crow YJ. Cerebroretinal microangiopathy with calcifications and cysts (CRMCC). *Am J Med Genet A*. 2008;146A:182–90. PubMed PMID: 18076099.
- Burris AM, Ballew BJ, Kentosh JB, Turner CE, Norton SA, Giri N, Alter BP, Nellan A, Gamper C, Hartman KR, Savage SA, et al. Høyeraal-Hreidarsson syndrome due to PARN mutations: fourteen years of follow-up. *Pediatr Neurol*. 2016;56:62–8.e1. PubMed PMID: 26810774.
- Denny CC, Wilfond BS, Peters JA, Giri N, Alter BP. All in the family: disclosure of "unwanted" information to an adolescent to benefit a relative. *Am J Med Genet A*. 2008;146A:2719–24. PubMed PMID: 18831063.
- Dodson LM, Baldan A, Nissbeck M, Gunja SMR, Bonnen PE, Aubert G, Birchansky S, Virtanen A, Bertuch AA. From incomplete penetrance with normal telomere length to severe disease and telomere shortening in a

- family with monoallelic and biallelic PARN pathogenic variants. *Hum Mutat.* 2019;40:2414–29. PubMed PMID: 31448843.
- Dokal I. Dyskeratosis congenita. *Hematology Am Soc Hematol Educ Program.* 2011;2011:480–6. PubMed PMID: 22160078.
- Dokal I, Vulliamy T, Mason P, Bessler M. Clinical utility gene card for: dyskeratosis congenita - update 2015. *Eur J Hum Genet.* 2015.:23.
- Eiler ME, Frohnmayer D, Frohnmayer L, Larsen K, Owen J, eds. *Fanconi Anemia: Guidelines for Diagnosis and Management.* 3 ed. Fanconi Anemia Research Fund, Inc. Available [online](#). 2008. Accessed 1-13-23.
- Fioredda F, Iacobelli S, Korthof ET, Knol C, van Biezen A, Bresters D, Veys P, Yoshimi A, Fagioli F, Mats B, Zecca M, Faraci M, Miano M, Arcuri L, Maschan M, O'Brien T, Diaz MA, Sevilla J, Smith O, Peffault de Latour R, de la Fuente J, Or R, Van Lint MT, Tolar J, Aljurf M, Fisher A, Skorobogatova EV, Diaz de Heredia C, Risitano A, Dalle JH, Sedláček P, Ghavamzadeh A, Dufour C. Outcome of haematopoietic stem cell transplantation in dyskeratosis congenita. *Br J Haematol.* 2018;183:110–18. PubMed PMID: 29984823.
- Fogarty PF, Yamaguchi H, Wiestner A, Baerlocher GM, Sloand E, Zeng WS, Read EJ, Lansdorp PM, Young NS. Late presentation of dyskeratosis congenita as apparently acquired aplastic anaemia due to mutations in telomerase RNA. *Lancet.* 2003;362:1628–30. PubMed PMID: 14630445.
- Gable DL, Gaysinskaya V, Atik CC, Talbot CC Jr, Kang B, Stanley SE, Pugh EW, Amat-Codina N, Schenk KM, Arcasoy MO, Brayton C, Florea L, Armanios M. ZCCHC8, the nuclear exosome targeting component, is mutated in familial pulmonary fibrosis and is required for telomerase RNA maturation. *Genes Dev.* 2019;33:1381–96. PubMed PMID: 31488579.
- Giri N, Pitel PA, Green D, Alter BP. Splenic peliosis and rupture in patients with dyskeratosis congenita on androgens and granulocyte colony-stimulating factor. *Br J Haematol.* 2007;138:815–17. PubMed PMID: 17760812.
- Giri N, Ravichandran S, Wang Y, Gadalla SM, Alter BP, Fontana J, Savage SA. Prognostic significance of pulmonary function tests in dyskeratosis congenita, a telomere biology disorder. *ERJ Open Res.* 2019;5:00209–2019.
- Glousker G, Touzot F, Revy P, Tzfati Y, Savage SA. Unraveling the pathogenesis of Hoyeraal-Hreidarsson syndrome, a complex telomere biology disorder. *Br J Haematol.* 2015;170:457–71. PubMed PMID: 25940403.
- Gorgy AI, Jonassaint NL, Stanley SE, Koteish A, DeZern AE, Walter JE, Sopha SC, Hamilton JP, Hoover-Fong J, Chen AR, Anders RA, Kamel IR, Armanios M. Hepatopulmonary syndrome is a frequent cause of dyspnea in the short telomere disorders. *Chest.* 2015;148:1019–26. PubMed PMID: 26158642.
- Guo Y, Kartawinata M, Li J, Pickett HA, Teo J, Kilo T, Barbaro PM, Keating B, Chen Y, Tian L, Al-Odaib A, Reddel RR, Christodoulou J, Xu X, Hakonarson H, Bryan TM. Inherited bone marrow failure associated with germline mutation of ACD, the gene encoding telomere protein TPP1. *Blood.* 2014;124:2767–74. PubMed PMID: 25205116.
- Gutierrez-Rodriguez F, Donaires FS, Pinto A, Vicente A, Dillon LW, Clé DV, Santana BA, Pirooznia M, Ibanez MDPF, Townsley DM, Kajigaya S, Hourigan CS, Cooper JN, Calado RT, Young NS. Pathogenic TERT promoter variants in telomere diseases. *Genet Med.* 2019;21:1594–602. PubMed PMID: 30523342.
- Higgs C, Crow YJ, Adams DM, Chang E, Hayes D Jr, Herbig U, Huang JN, Himes R, Jajoo K, Johnson FB, Reynolds SD, Yonekawa Y, Armanios M, Boulad F, DiNardo CD, Dufour C, Goldman FD, Khan S, Kratz C, Myers KC, Raghu G, Alter BP, Aubert G, Bhala S, Cowen EW, Dror Y, El-Youssef M, Friedman B, Giri N, Helms Guba L, Khincha PP, Lin TF, Longhurst H, McReynolds LJ, Nelson A, Olson T, Pariser A, Perona R, Sasa G, Schratz K, Simonetto DA, Townsley D, Walsh M, Stevens K, Agarwal S, Bertuch AA, Savage SA, et al. Understanding the evolving phenotype of vascular complications in telomere biology disorders. *Angiogenesis.* 2019;22:95–102. PubMed PMID: 30168024.

- Hirvonen EAM, Peuhkuri S, Norberg A, Degerman S, Hannula-Jouppi K, Välimaa H, Kilpivaara O, Wartiovaara-Kautto U. Characterization of an X-chromosome-linked telomere biology disorder in females with DKC1 mutation. *Leukemia*. 2019;33:275–8. PubMed PMID: 30185935.
- Hoyeraal HM, Lamvik J, Moe PJ. Congenital hypoplastic thrombocytopenia and cerebral malformations in two brothers. *Acta Paediatr Scand*. 1970;59:185–91. PubMed PMID: 5442429.
- Hreidarsson S, Kristjansson K, Johannesson G, Johannesson JH. A syndrome of progressive pancytopenia with microcephaly, cerebellar hypoplasia and growth failure. *Acta Paediatr Scand*. 1988;77:773–5. PubMed PMID: 3201986.
- Huang SJ, Amendola LM, Sternen DL. Variation among DNA banking consent forms: points for clinicians to bank on. *J Community Genet*. 2022;13:389–97. PubMed PMID: 35834113.
- Jongmans MC, Verwiel ET, Heijdra Y, Vulliamy T, Kamping EJ, Hehir-Kwa JY, Bongers EM, Pfundt R, van Emst L, van Leeuwen FN, van Gassen KL, Geurts van Kessel A, Dokal I, Hoogerbrugge N, Ligtenberg MJ, Kuiper RP. Revertant somatic mosaicism by mitotic recombination in dyskeratosis congenita. *Am J Hum Genet*. 2012;90:426–33. PubMed PMID: 22341970.
- Jónsson H, Sulem P, Kehr B, Kristmundsdóttir S, Zink F, Hjartarson E, Hardarson MT, Hjorleifsson KE, Eggertsson HP, Gudjonsson SA, Ward LD, Arnadóttir GA, Helgason EA, Helgason H, Gylfason A, Jonasdóttir A, Jonasdóttir A, Rafnar T, Frigge M, Stacey SN, Th Magnusson O, Thorsteinsdóttir U, Masson G, Kong A, Halldorsson BV, Helgason A, Gudbjartsson DF, Stefansson K. Parental influence on human germline de novo mutations in 1,548 trios from Iceland. *Nature*. 2017;549:519–22. PubMed PMID: 28959963.
- Kapuria D, Ben-Yakov G, Ortolano R, Cho MH, Kalchiem-Dekel O, Takyar V, Lingala S, Gara N, Tana M, Kim YJ, Kleiner DE, Young NS, Townsley DM, Koh C, Heller T. The spectrum of hepatic involvement in patients with telomere disease. *Hepatology*. 2019;69:2579–85. PubMed PMID: 30791107.
- Khincha PP, Bertuch AA, Agarwal S, Townsley DM, Young NS, Keel S, Shimamura A, Boulad F, Simoneau T, Justino H, Kuo C, Artandi S, McCaslin C, Cox DW, Chaffee S, Collins BF, Giri N, Alter BP, Raghu G, Savage SA. Pulmonary arteriovenous malformations: an uncharacterised phenotype of dyskeratosis congenita and related telomere biology disorders. *Eur Respir J*. 2017;49:1601640. PubMed PMID: 27824607.
- Khincha PP, Wentzensen IM, Giri N, Alter BP, Savage SA. Response to androgen therapy in patients with dyskeratosis congenita. *Br J Haematol*. 2014;165:349–57. PubMed PMID: 24666134.
- Kocak H, Ballew BJ, Bisht K, Eggebeen R, Hicks BD, Suman S, O'Neil A, Giri N, Maillard I, Alter BP, Keegan CE, Nandakumar J, Savage SA, et al. Hoyeraal-Hreidarsson syndrome caused by a germline mutation in the TEL patch of the telomere protein TPP1. *Genes Dev*. 2014;28:2090–102. PubMed PMID: 25233904.
- Linnankivi T, Valanne L, Paetau A, Alafuzoff I, Hakumäki JM, Kivelä T, Lönnqvist T, Mäkitie O, Pääkkönen L, Vainionpää L, Vanninen R, Herva R, Pihko H. Cerebroretinal microangiopathy with calcifications and cysts. *Neurology*. 2006;67:1437–43. PubMed PMID: 16943371.
- Maryoung L, Yue Y, Young A, Newton CA, Barba C, van Oers NS, Wang RC, Garcia CK. Somatic mutations in telomerase promoter counterbalance germline loss-of-function mutations. *J Clin Invest*. 2017;127:982–6. PubMed PMID: 28192371.
- Moon DH, Segal M, Boyraz B, Guinan E, Hofmann I, Cahan P, Tai AK, Agarwal S. Poly(A)-specific ribonuclease (PARN) mediates 3'-end maturation of the telomerase RNA component. *Nat Genet*. 2015;47:1482–8. PubMed PMID: 26482878.
- Niewisch MR, Giri N, McReynolds LJ, Alsaggaf R, Bhala S, Alter BP, Savage SA. Disease progression and clinical outcomes in telomere biology disorders. *Blood*. 2022;139:1807–19. PubMed PMID: 34852175.
- Niewisch MR, Savage SA. An update on the biology and management of dyskeratosis congenita and related telomere biology disorders. *Expert Rev Hematol*. 2019;12:1037–52. PubMed PMID: 31478401.

- Podlevsky JD, Bley CJ, Omana RV, Qi X, Chen JJ-L. The telomerase database. *Nucleic Acids Res.* 2008;36:D339–D343. PubMed PMID: 18073191.
- Polvi A, Linnankivi T, Kivelä T, Herva R, Keating JP, Mäkitie O, Pareyson D, Vainionpää L, Lahtinen J, Hovatta I, Pihko H, Lehesjoki AE. Mutations in CTC1, encoding the CTS telomere maintenance complex component 1, cause cerebrotelomeric microangiopathy with calcifications and cysts. *Am J Hum Genet.* 2012;90:540–9. PubMed PMID: 22387016.
- Revesz T, Fletcher S, al Gazali LI, DeBuse P. Bilateral retinopathy, aplastic anaemia, and central nervous system abnormalities: a new syndrome? *J Med Genet.* 1992;29:673–5. PubMed PMID: 1404302.
- Richards S, Aziz N, Bale S, Bick D, Das S, Gastier-Foster J, Grody WW, Hegde M, Lyon E, Spector E, Voelkerding K, Rehm HL, et al. Standards and guidelines for the interpretation of sequence variants: a joint consensus recommendation of the American College of Medical Genetics and Genomics and the Association for Molecular Pathology. *Genet Med.* 2015;17:405–24. PubMed PMID: 25741868.
- Sasa GS, Ribes-Zamora A, Nelson ND, Bertuch AA. Three novel truncating TIN2 mutations causing severe dyskeratosis congenita in early childhood. *Clin Genet.* 2012;81:470–8. PubMed PMID: 21477109.
- Savage SA, Bertuch AA. The genetics and clinical manifestations of telomere biology disorders. *Genet Med.* 2010;12:753–64. PubMed PMID: 21189492.
- Savage SA, Cook EF, eds. *Dyskeratosis Congenita and Telomere Biology Disorders: Diagnosis and Management Guidelines*. Dyskeratosis Congenita Outreach, Inc. Available [online](#). 2015. Accessed 1-13-23.
- Savage SA, Dokal I, Armanios M, Aubert G, Cowen EW, Domingo DL, Giri N, Greene MH, Orchard PJ, Tolar J, Tsilou E, Van Waes C, Wong JM, Young NS, Alter BP. Dyskeratosis congenita: the first NIH clinical research workshop. *Pediatr Blood Cancer.* 2009;53:520–3. PubMed PMID: 19415736.
- Savage SA, Giri N, Baerlocher GM, Orr N, Lansdorp PM, Alter BP. TIN2, a component of the shelterin telomere protection complex, is mutated in dyskeratosis congenita. *Am J Hum Genet.* 2008;82:501–9. PubMed PMID: 18252230.
- Shao Y, Feng S, Huang J, Huo J, You Y, Zheng Y. A unique homozygous WRAP53 Arg298Trp mutation underlies dyskeratosis congenita in a Chinese Han family. *BMC Med Genet.* 2018;19:40. PubMed PMID: 29514627.
- Sharma R, Sahoo SS, Honda M, Granger SL, Goodings C, Sanchez L, Kunstner A, Busch H, Beier F, Pruett-Miller SM, Valentine MB, Fernandez AG, Chang TC, Geli V, Churikov D, Hirschi S, Pastor VB, Boerries M, Lauten M, Kelaidi C, Cooper MA, Nicholas S, Rosenfeld JA, Polychronopoulou S, Kannengiesser C, Saintome C, Niemeyer CM, Revy P, Wold MS, Spies M, Erlacher M, Coulon S, Wlodarski MW. Gain-of-function mutations in RPA1 cause a syndrome with short telomeres and somatic genetic rescue. *Blood.* 2022;139:1039–51. PubMed PMID: 34767620.
- Shi L, Webb BD, Birch AH, Elkhoury L, McCarthy J, Cai X, Oishi K, Mehta L, Diaz GA, Edelmann L, Kornreich R. Comprehensive population screening in the Ashkenazi Jewish population for recurrent disease-causing variants. *Clin Genet.* 2017;91:599–604. PubMed PMID: 27415407.
- Simon AJ, Lev A, Zhang Y, Weiss B, Rylova A, Eyal E, Kol N, Barel O, Cesarkas K, Soudack M, Greenberg-Kushnir N, Rhodes M, Wiest DL, Schiby G, Barshack I, Katz S, Pras E, Poran H, Reznik-Wolf H, Ribakovsky E, Simon C, Hazou W, Sidi Y, Lahad A, Katzir H, Sagie S, Aqeilan HA, Glousker G, Amariglio N, Tzfati Y, Selig S, Rechavi G, Somech R. Mutations in STN1 cause Coats plus syndrome and are associated with genomic and telomere defects. *J Exp Med.* 2016;213:1429–40. PubMed PMID: 27432940.
- Stanley SE, Gable DL, Wagner CL, Carlisle TM, Hanumanthu VS, Podlevsky JD, Khalil SE, DeZern AE, Rojas-Duran MF, Applegate CD, Alder JK, Parry EM, Gilbert WV, Armanios M. Loss-of-function mutations in the RNA biogenesis factor NAF1 predispose to pulmonary fibrosis-emphysema. *Sci Transl Med.* 2016;8:351ra107.

- Stenson PD, Mort M, Ball EV, Chapman M, Evans K, Azevedo L, Hayden M, Heywood S, Millar DS, Phillips AD, Cooper DN. The Human Gene Mutation Database (HGMD®): optimizing its use in a clinical diagnostic or research setting. *Hum Genet.* 2020;139:1197–207. PubMed PMID: 32596782.
- Takai H, Jenkinson E, Kabir S, Babul-Hirji R, Najm-Tehrani N, Chitayat DA, Crow YJ, de Lange T. A. POT1 mutation implicates defective telomere end fill-in and telomere truncations in Coats plus. *Genes Dev.* 2016;30:812–26. PubMed PMID: 27013236.
- Townsley DM, Dumitriu B, Young NS. Danazol treatment for telomere diseases. *N Engl J Med.* 2016;375:1095–6.
- Tsangaris E, Adams SL, Yoon G, Chitayat D, Lansdorp P, Dokal I, Dror Y. Ataxia and pancytopenia caused by a mutation in TINF2. *Hum Genet.* 2008;124:507–13. PubMed PMID: 18979121.
- Tummala H, Walne A, Collopy L, Cardoso S, de la Fuente J, Lawson S, Powell J, Cooper N, Foster A, Mohammed S, Plagnol V, Vulliamy T, Dokal I. Poly(A)-specific ribonuclease deficiency impacts telomere biology and causes dyskeratosis congenita. *J Clin Invest.* 2015;125:2151–60. PubMed PMID: 25893599.
- van der Vis JJ, van der Smagt JJ, Hennekam FAM, Grutters JC, van Moorsel CHM. Pulmonary fibrosis and a TERT founder mutation with a latency period of 300 years. *Chest.* 2020;158:612–9. PubMed PMID: 32315675.
- Velazquez I, Alter BP. Androgens and liver tumors: Fanconi's anemia and non-Fanconi's conditions. *Am J Hematol.* 2004;77:257–67. PubMed PMID: 15495253.
- Vulliamy T, Beswick R, Kirwan M, Marrone A, Digweed M, Walne A, Dokal I. Mutations in the telomerase component NHP2 cause the premature ageing syndrome dyskeratosis congenita. *Proc Natl Acad Sci USA.* 2008;105:8073–8. PubMed PMID: 18523010.
- Vulliamy TJ, Marrone A, Knight SW, Walne A, Mason PJ, Dokal I. Mutations in dyskeratosis congenita: their impact on telomere length and the diversity of clinical presentation. *Blood.* 2006;107:2680–5. PubMed PMID: 16332973.
- Walne AJ, Dokal I. Dyskeratosis congenita: a historical perspective. *Mech Ageing Dev.* 2008;129:48–59. PubMed PMID: 18054794.
- Walne AJ, Vulliamy T, Beswick R, Kirwan M, Dokal I. TINF2 mutations result in very short telomeres: analysis of a large cohort of patients with dyskeratosis congenita and related bone marrow failure syndromes. *Blood.* 2008;112:3594–600. PubMed PMID: 18669893.
- Walne AJ, Vulliamy T, Marrone A, Beswick R, Kirwan M, Masunari Y, Al Qurashi FH, Aljurf M, Dokal I. Genetic heterogeneity in autosomal recessive dyskeratosis congenita with one subtype due to mutations in the telomerase-associated protein NOP10. *Hum Mol Genet.* 2007;16:1619–29. PubMed PMID: 17507419.
- Ward SC, Savage SA, Giri N, Alter BP, Rosenberg PS, Pichard DC, Cowen EW. Beyond the triad: Inheritance, mucocutaneous phenotype, and mortality in a cohort of patients with dyskeratosis congenita. *J Am Acad Dermatol.* 2018;78:804–6. PubMed PMID: 29042228.
- Xu J, Khincha PP, Giri N, Alter BP, Savage SA, Wong JM. Investigation of chromosome X inactivation and clinical phenotypes in female carriers of DKC1 mutations. *Am J Hematol.* 2016;91:1215–20. PubMed PMID: 27570172.
- Young NS. Aplastic anemia. *N Engl J Med.* 2018;379:1643–56. PubMed PMID: 30354958.
- Zeng T, Lv G, Chen X, Yang L, Zhou L, Dou Y, Tang X, Yang J, An Y, Zhao X. CD8+ T-cell senescence and skewed lymphocyte subsets in young dyskeratosis congenita patients with PARN and DKC1 mutations. *J Clin Lab Anal.* 2020;34:e23375. PubMed PMID: 32452087.
- Zhong F, Savage SA, Shkreli M, Giri N, Jessop L, Myers T, Chen R, Alter BP, Artandi SE. Disruption of telomerase trafficking by TCAB1 mutation causes dyskeratosis congenita. *Genes Dev.* 2011;25:11–16. PubMed PMID: 21205863.

License

GeneReviews® chapters are owned by the University of Washington. Permission is hereby granted to reproduce, distribute, and translate copies of content materials for noncommercial research purposes only, provided that (i) credit for source (<http://www.genereviews.org/>) and copyright (© 1993-2024 University of Washington) are included with each copy; (ii) a link to the original material is provided whenever the material is published elsewhere on the Web; and (iii) reproducers, distributors, and/or translators comply with the [GeneReviews® Copyright Notice and Usage Disclaimer](#). No further modifications are allowed. For clarity, excerpts of GeneReviews chapters for use in lab reports and clinic notes are a permitted use.

For more information, see the [GeneReviews® Copyright Notice and Usage Disclaimer](#).

For questions regarding permissions or whether a specified use is allowed, contact: admasst@uw.edu.